

Chief Medical Examiner
Margaret S. Greenwald, M.D.

Deputy Chief Medical Examiner
Michael Ferenc, M.D.



1096

Telephone: (207) 624-7180
FAX: (207) 624-7178

OFFICE OF CHIEF MEDICAL EXAMINER

37 State House Station
Augusta, Maine 04333-0037

Date: 5/12/01

Dear: Mr. Carter

All requests for copies of records held by this office must be made on this form. One mailing will be made; only after all items requested are completed and all applicable fees have been received. Make check or money order payable to Treasurer of the State of Maine, please do not send cash. Also, enclose a self addressed legal size envelope with _____ postage attached. (If envelope sent with original request, disregard this requirement.)

One copy of the records will be provided to the legal next of kin, investigating agency and doctor of record at no charge, but a self addressed, stamped envelope is still required. All other items listed on the order form will be charged for. If you have any questions, please call (207) 624-7180.

RECORDS REQUEST/FEE LIST

RE: Karoly Bartua

Case # 2000-1862-A

| Available when complete: | Price | # requested | amount enclosed: |
|---|-------------|-------------|------------------|
| <input checked="" type="checkbox"/> Report Documents (no autopsy) | \$10.00 | _____ | \$ _____ |
| <input checked="" type="checkbox"/> Report Documents (with autopsy) | \$25.00 | _____ | \$ _____ |
| <input type="checkbox"/> Certified Copy of Reports | \$35.00 | _____ | \$ _____ |
| <input type="checkbox"/> Histological Slides: | | | |
| Number of slides _____ | \$10.00 ea. | _____ | \$ _____ |
| Handling fee | \$20.00 | _____ | \$ _____ |
| Additional handling fee for more than 20 slides | \$20.00 | _____ | \$ _____ |
| <input type="checkbox"/> Other Items or Services | | | \$ _____ |
| Costs + shipping + \$20.00 | | | |
| Handling Fee | | | \$ _____ |
| Includes: _____ | | | |
| _____ | | | |
| _____ | | | |

TOTAL \$ _____

Mail ordered material to: Attn: Chris Carter

Name: N.H. AG's Office Phone Number _____

Address: 35 Capitol St FAX: _____

Concord, NH ZIP: 03301

sent 4/13/01:
NEO-Gen Screening
SCOD
TCX
MIE Report
Autopsy
Diagrams (7)
Growth Chart
Neuro-Pat
tax

Angus S. King, Jr.
Governor



1097

Kevin W. Concannon, Jr.
Commissioner

COPY

STATE OF MAINE
DEPARTMENT OF HUMAN SERVICES
AUGUSTA, MAINE 04333-0011

SUPPLEMENTAL CERTIFICATE OF DEATH

Date: April 12, 2001

TO: Vital Statistics

FROM: Margaret S. Greenwald, M.D., Chief Medical Examiner

DECEDENT: Kassidy Bortner, 2000-1862 Date of Death: 11/9/2000, York, ME

The death certificate of the above named decedent contains the medical certification of the cause of death which appears below.

To properly classify this death for statistical purposes, please furnish us with the information requested. Return this form in the enclosed self addressed envelope to: CHIEF MEDICAL EXAMINER, #37 STATE HOUSE STATION, AUGUSTA, MAINE 04333.

CAUSE OF DEATH SUPPLEMENT

| | | | | |
|--|--|--|---|--|
| 40. WAS AN AUTOPSY PERFORMED? YES <input type="checkbox"/> NO <input type="checkbox"/> | 42. MANNER OF DEATH <input type="checkbox"/> Natural <input type="checkbox"/> Accident <input type="checkbox"/> Suicide <input checked="" type="checkbox"/> Homicide <input type="checkbox"/> Pending Investigation <input type="checkbox"/> Could Not Be Determined | 43. INJURY AT WORK <input type="checkbox"/> YES <input checked="" type="checkbox"/> NO | 44. DATE OF INJURY (Mo, Day, Yr) Unknown | 45. DESCRIBE HOW INJURY OCCURRED Assaulted by another |
| 41. WERE AUTOPSY FINDINGS AVAILABLE PRIOR TO COMPLETION OF CAUSE OF DEATH? YES <input checked="" type="checkbox"/> NO <input type="checkbox"/> | | | 46. TIME OF INJURY Unknown <input type="checkbox"/> AM <input type="checkbox"/> PM | 47. PLACE OF INJURY - At home, farm, street, factory, office building, etc. (Specify) Unknown |
| | | | | 48. LOCATION - Street and Number or Rural Route Number, City or Town, State Unknown |
| 49. PART I. Enter the diseases, injuries, or complications which caused the death. Do not enter the mode of dying, such as cardiac or respiratory arrest, shock, or heart failure. List only one cause on each line. | | | | |
| CONFIDENTIAL | IMMEDIATE CAUSE (Final disease or condition resulting in death) a. <u>Multiple Blunt Force Injuries</u> | | | |
| | b. <u>_____</u> DUE TO (OR AS A CONSEQUENCE OF): | | | |
| | c. <u>_____</u> DUE TO (OR AS A CONSEQUENCE OF): | | | |
| | d. <u>_____</u> DUE TO (OR AS A CONSEQUENCE OF): | | | |
| PART II. <u>Other significant conditions</u> contributing to death but not resulting in the underlying cause given in Part I. | | | | |

SOURCE:

Police Report ☐

Medical Examiner Report ☐

Teletype ☐

ITEMS CHANGED: 41 - 49

PHYSICIAN'S SIGNATURE: [Signature]

DATE: 4/12/2001

STATE OF MAINE
REPORT OF INQUIRY AND EXAMINATION BY MEDICAL EXAMINER

CASE #: 2000-1862A

DECEDENT: Kassidy BortnerBIRTH DATE: 2/4/99AGE: 21 monthsADDRESS: 2 Mousan Street, Springvale, MESEX: FRACE: White

1098

NOTIFIED BY: York Hospital Emergency RoomDATE AND TIME: 11/9/00; 1:50 PMPOLICE INVESTIGATOR: Sgt. Matt StewartDEPT: Maine State Police, CID I

(Write None If Applicable)

INFORMANT: (Including Relationship to Deceased) Sgt Stewart, York Hospital Medical Records, Maine Assistant AGFern LaRochelle, NH Assistant AG Chris CarterPLACE OF DEATH: York Hospital Emergency RoomSCENE VISIT: (DATE AND TIME OR NONE) NONEPLACE BODY EXAMINED: OCME DATE AND TIME: November 10, 2000, 9:00 AM - 2:45 PM and November 14, 2000; 1:30 PM-2:30 PM

IMMEDIATE CAUSE:

(a) Multiple blunt force injuries

DUE TO, OR AS A CONSEQUENCE OF:

(b) _____

DUE TO, OR AS A CONSEQUENCE OF:

(c) _____

OTHER SIGNIFICANT CONDITIONS:

| | | |
|--|----------------------------------|---|
| MANNER: (Accident, Suicide, etc) Homicide | DATE & TIME OF INJURY Unknown | HOW INJURY OCCURRED Assaulted by another |
| AT WORK? NO | PLACE OF INJURY Unknown | LOCATION Unknown |

DATE AND TIME OF DEATH: November 9, 2000; 1:28 PMDATE AND TIME FOUND: N/ALAST SEEN ALIVE: N/AAUTOPSY AUTHORIZED BY: Margaret Greenwald, MD; CME
(Name and Title)PATHOLOGIST: M. GreenwaldBODY RELEASED TO: Adam's Funeral HomeTOXICOLOGY OR OTHER STUDIES PENDING: Multiple studies

I hereby declare that the information contained herein regarding this death is true and correct to the best of my knowledge and belief, as is the information contained on the death certificate if signed by me.

November 15, 2000

York

Date

County of Death

Signature of Medical Examiner

Typed or Printed Name of Medical Examiner: Margaret Greenwald, MD; Chief Medical Examiner

ORIGINAL TO BE FILED WITH CHIEF MEDICAL EXAMINER, STATE HOUSE STATION 37, AUGUSTA, ME 04333

MEDICAL AND OTHER PERSONAL HISTORY: Including Name of Physician or Institution, Diagnosis, Date and Previous Injuries

Mother was a 16 year old G1P0. Child was born by spontaneous vaginal delivery, full term at Southern Maine Medical Center on 2/4/99. No significant complications. Birth weight 8 lbs, 12 oz., length 21 ½ inches, head circumference: 13 ½ inches, chest circumference: 13 ½ inches.

In September of 1999, was seen by Dr. James Timoney for evaluation of 'in-toed' gait. On that date, no injuries are noted by the physician. There is no indication of X-rays, but an orthopedic examination is performed. The decedent is described as cranky, but this is attributed to her missing her nap. Mother says that the growth milestones have been normal and she began walking at about 8 months.

DESCRIPTION OF BODY

POSITION OF BODY WHEN FOUND AT PLACE OF DEATH: N/A

CLOTHING AND OTHER ITEMS ON BODY:

APPARENT AGE: SEX: COLOR:

DEVELOPMENT: NUTRITION: HEIGHT: WEIGHT:

HAIR-SCALP: FACE:

EYES-COLOR: PETECHIAE: OTHER:

MOUTH-DENTITION: FLUID:

EXTERNAL GENITALIA:

SCARS, TATOOS, ANOMALIES:

PRESERVATION: HEAT:

RIGIDITY-DEGREE AND LOCATION:

LIVIDITY-COLOR AND LOCATION:

EXTERNAL PATHOLOGY AND OTHER FINDINGS:

(Diagram may be used to supplement description - if an autopsy has been, ordered, less detailed description of the body may suffice)

*for fractures-note location and extent

cuts-cleanly incised or irregular, location, length, depth

gunshot wounds- location, size, powder burns, smoke marks, shape of holes, exit and entrance, — approximate track and direction, if projectile recovered, marks on clothing

blunt trauma and ligature marks-size, pattern, location

burns-extent in depth and area

1100

See autopsy report.

NARRATIVE SUMMARY OF CIRCUMSTANCES AND DESCRIPTION OF SCENE: include as applicable description of premises, temperature, weather if outdoors, alcoholism, drug use, type of weapons at scene, indication of suicide - note, despondent over, verbal threats, etc. Auto accident - driver, passenger, pedestrian, etc., single car or other vehicles. PLEASE NOTE: This information has been received during the course of the investigation and is subject to subsequent confirmation.

The decedent was described to be in her usual state of health by babysitter on Wednesday afternoon when he was with this 21 month old female from about 3:30 PM. She had been dropped off at his home. He indicates to investigators that she was picked up by the mother's boyfriend (who resides in NH) at about 5:00 or 6:00 PM. The boyfriend was in charge of Kassidy between that time and midnight when mother returns home. The only other person in the house was the boyfriend's 3 year old child. When mother came home, she did not try to wake Kassidy by her statement to investigators, but she did describe the presence of a 'bruise' on her cheek.

At about 6AM Kassidy was either awakened by mom or wakened on her own, was lethargic and crying. Her eyes were described as 'rolling around'. She was taken back to the babysitters in Kittery

about 8:30 AM. This time both mom's sister and the aunt's boyfriend (who is the babysitter) were present and mom pointed out to them the bruising.

The babysitter describes Kassidy as lethargic all day. She was offered food but apparently did not eat. About Noon, the babysitter found Kassidy unresponsive. Rescue and Kittery PD were called. It was immediately apparent that there was bruising. Photos were taken and the decedent was transported to York Hospital but was essentially DOA. Examination disclosed retinal hemorrhage, diffuse.

The decedent was pronounced dead at 1:28 PM.

— 1101

KASSIDY BORTNER

2000-1862A

OFFICE OF CHIEF MEDICAL EXAMINER
STATE OF MAINE

State House Station 37, Augusta, Maine 04333
Tel. 207 624 7180 Fax. 207 624 7178

CASE SUMMARY FOR: 2000-1862A

Decedent's name: Kassidy Bortner

Date of autopsy: November 10, 2000

Studies performed: autopsy (x), toxicology (x), histology (x), neuropathology (x),
other studies (x) genetics studies, blood cultures, vitreous chemistries

FINDINGS

- I. Head trauma
 - a. Acute subdural hematoma over basilar skull (minimally adherent) and convexities.
 - b. Subarachnoid hemorrhage, right temporal lobe.
 - c. Multiple areas of recent subgaleal contusion, right posterior and superior scalp, left superior scalp, right supraorbital scalp.
 - d. Areas of healing and remote contusions involving right superior scalp and right supraorbital scalp.
 - e. Cerebral edema.
 - f. Anoxic changes, neocortex (See neuropathology examination).
 - g. Multiple areas of facial bruising.
 - h. Bilateral acute retinal and optic nerve hemorrhage with focal hemosiderin deposition.
- II. Abdominal trauma
 - a. Multiple irregular brown contusions of skin, anterior abdomen.
 - b. Minimal acute hemorrhage in rectus abdominus muscle.
 - c. Recent hemorrhage with early reactive inflammation in sections of mesentery and small intestine.
- III. Systemic fat emboli.
- IV. Hair loss, posterior scalp.
- V. Recent contusion/laceration of labial mucosa, lower lip.
- VI. Frenulum with area of acute contusion and reparative change on microscopic examination.
- VII. Left buccal mucosa, recent denudation of mucosal surface with older reparative and atrophic changes.
- VIII. Crusted abrasions of upper and lower lips.
- IX. Contusions of bilateral anterior tongue.
- X. Multiple areas of recent contusion to jaw and neck.
- XI. Multiple areas of superficial injury to soles of both feet (spread over the area of the

KASSIDY BORTNER


2000-1862A

- arch).
- XII. Multiple contusions of torso and extremities in various stages from acute to healing.
 - XIII. Left tibia, fracture in remodeling stage changes with re-injury and secondary fracture in the Inflammatory stage .
 - XIV. Fractures of ulna, bilateral, Late reparative to early remodeling stage
 - XV. Fracture of right 2nd metacarpal, Reparative stage.

NOTE: All diagnoses of skin lesions and fractures are descriptive and use general terms. Histologic aging of bruises or fractures is primarily based on standards in adults. Children are known to heal much more quickly. Additionally, the time required to heal may vary from person to person or from one anatomic site to another on an individual. In general, bruises are diagnosed as acute, recent, or healing with specific histologic descriptions in the microscopic examination. Fractures are classified as inflammatory stage, reparative stage and remodeling stage.

CAUSE OF DEATH: Multiple blunt force injuries

MANNER OF DEATH: Homicide



Margaret Greenwald, MD
Chief Medical Examiner
April 6, 2001

KASSIDY BORTNER


2000-1862A

1104

**OFFICE OF CHIEF MEDICAL EXAMINER
STATE OF MAINE**

State House Station 37, Augusta, Maine 04333
Tel. 207 624 7180 Fax 207 624 7178

Name of Deceased: Kassidy Bortner **Residence:** 2 Mousan Street, Springvale, ME
Date and Time of Death: November 10, 2000; 1:28 PM.
Place of Death: York Hospital Emergency Room, York, ME
Sex: F **Reported Age:** 21 months (**DOB** 2/ 4/ 99)
Date and Time of Autopsy: November 11, 2000, 9: 00 AM-2: 45PM and November 14, 2000, 1:30PM-2:30 PM.

I hereby certify that I, , have performed an autopsy at the Office of Chief Medical Examiner on the person identified above and that the following is a true and accurate report of my findings.

PRELIMINARY EXAMINATION

The body is received in two white flannel blankets and has an appropriately labeled identification band on the right ankle.

The following items of clothing are present: None.

Sexual contact studies of labia, vagina, anus, and oral cavity are taken including smears and swabs for analysis. No foreign material is noted. Pulled head hair and fingernail clippings are also taken.

Swabs from the forehead and left cheek are also taken for DNA studies in the areas of the curvilinear contusions over the face and forehead.

MEDICAL INTERVENTION

There is a soft neck brace in place around the neck. There is an endotracheal tube in the mouth. There are intraosseous catheters in the anterior tibias bilaterally. These are covered by bandages. The skin over the right leg and the left lower leg have been washed with betadine. There is an electrocardiogram pad on the lower leg.

EXTERNAL INJURIES

HEAD AND NECK INJURIES:

There are multiple contusions of the scalp and face.

KASSIDY BORTNER

2000-1862A

The right inferior occipital scalp exhibits a tan contusion measuring 2.2 x 0.8 cm. The left mid occipital scalp exhibits a smaller red brown contusion which measures 1 x 0.4 cm. There is an area of reddish pale mottling over the mid posterior occipital scalp above the previously described injuries. The right mid posterior parietal scalp exhibits a tan brown contusion which measures 0.6 x 0.8 cm.

The left lateral forehead exhibits four irregularly rounded contusions. Just above the left eyebrow there is a red purple contusion which measures 0.5 x 0.5 cm. More superior on the forehead are two larger contusions measuring 0.8 x 0.5 cm and 1.5 x 0.8 cm. having a purple and reddish coloration respectively. Just at the hairline, above the previous contusions, is a minute red contusion measuring 0.3 x 0.2 cm.

The mid anterior forehead exhibits multiple contusions. The superior most contusion is oval shaped, red purple and measures 0.8 x 0.4 cm. To the left of this is a red purple curvilinear half moon shaped contusion (open upwards) measuring approximately 3 cm in length, with a width of 0.2 cm. The medial aspect of this contusion has a tent like shape which measures 0.5 x 0.3 cm. This extends inferior in an interrupted linear contusion which measures 2.2 cm in length by 0.2 cm in width. Just medial to the left eyebrow is a oval shaped purple contusion which measures 1 x 0.5 cm. There are two smaller irregular contusions above the right eyebrow; a faint red contusion measuring 0.4 x 0.2 cm, and a tan contusion measuring 0.3 cm.

The right ear exhibits a purple contusion in the mid helix which measures 1.0 x 0.4 cm. This contusion is apparent over both the anterior and posterior surfaces. There are 3-4 irregularly rounded contusions which range from 0.3 - 0.5 cm in greatest diameter and range in color from tan to red tan.

Beneath the right eye is red purple abrasion contusion which measure 0.8 x 0.2 cm, 0.6 x 0.2 cm and 0.3 x 0.2 cm. Underlying these injuries is a larger area of blue purple contusion which covers an area measuring 1 x 0.4 cm.

Just lateral to the left eye is an irregularly round purple contusion which measures 0.6 x 0.4 cm. There is a irregular purple mottled band like area which extends from the left side of the bridge of the nose, across the left zygomatic ridge and to the left cheek covering a zone measuring 4.5 x 1.5 cm. The inferior edge is relatively straight. Extending up to this area beneath the eye, from the lateral edge of the mouth, is a curvilinear red contusion which measures 4 x 0.2 cm. Both of these injuries curve around the contours of the cheek. Close to the mouth there are two short, almost parallel lines which extend down from the curvilinear contusion and measure approximately 0.5 x 0.2 cm each. Inferior to the main area of large contusion under the left eye is an area of clustered red petechial hemorrhages covering a zone measuring 1 x 0.5 cm. There is a very small red contusion lateral to the larger area beneath the left eye. This measures 0.2 cm in

greatest dimension. A similar small red tan contusion is inferior and lateral to the previously described areas, also measuring 0.2 cm in greatest dimension.

The vermillion zone of the upper lip exhibits two crusted dry tan abrasions which 0.5 x 0.2 cm each, one on the right lateral upper lip and one over the mid upper lip. Similarly on the same area of the lower lip are multiple small tan dry crusted abrasions which measure approximately 0.2 cm each. The frenulum over the upper lip is intact but there is a small red contusion over the right labial mucosa which extends minimally onto the gingival mucosa and measures 0.5 x 0.3 cm. The lower labial mucosa exhibits a large red brown area of contusion, laceration and abrasion which extends down to the base of the lips and around the frenulum and covers a zone measuring 1.8 x 0.8 cm. Within this area of contusion, on the frenulum is a focal, pale punched out ulcer-like area which measures 0.2 cm.

The neck and chin area also disclose multiple contusions.

There is an irregularly oval red purple contusion along the angle of the mandible on the left, which measures 1.8 x 1.0 cm. Slightly superior to this lesion is a round tan contusion which measures 0.5 cm in greatest dimension. Along the inferior mandible, extending from the right mid jaw to the anterior mandible is a area of tan contusion with overlying smaller, darker defined contusions. The poorly defined area measures 5 x 1 cm. Smaller rounded areas are present over:

1. The left anterior mentum which measures 0.6 x 0.8 cm
2. Over the right anterior mentum, dark red measuring 1.8 x 1.0 cm.
3. Over the lateral right mid mentum, red and measuring 0.4 x 0.3 cm.
4. Over the inferior right mid mentum, tan and measuring 0.8 x 0.4 cm.

The right inferior neck exhibits a red brown, irregularly round contusion which measures 1 cm in greatest diameter. The left inferolateral neck exhibits a tan contusion which measures 0.5 x 0.3 cm in greatest dimension.

TORSO INJURIES:

The right anterior shoulder exhibits two red brown contusions measuring 0.3 cm and 0.4 cm in greatest dimension. The right lateral chest exhibits a round brown contusion which measures 0.5 cm. The right lateral hip exhibits three irregularly round tan apparent contusions which measure 0.8 x 0.3 cm, 1 x 0.4 cm, and 0.5 x 0.2 cm. The left lateral hip exhibits three irregular contusions distinct from the underlying lividity which are described as follows 0.5 x 0.3 cm, tan; 0.8 x 0.4 cm, red tan; and 0.4 x 0.2 cm, tan.

There are multiple tan to dark red brown contusions over the anterior abdomen.

The left side, slightly above the line of the umbilicus exhibits two light tan, poorly defined contusions which measure 0.4 cm in greatest dimension and 0.8 x 0.4 cm in greatest dimensions.

Lateral to these two, along the same horizontal line, is an angular darker red contusion measuring 1 cm along the horizontal and 1 cm along the vertical edges and having rounded, darker marks within this area which average 0.4 cm in greatest diameter each, located at the right angle, the most horizontal end and the most vertical end of each arm. To the left of the umbilicus and extending over the lower abdomen are two darker red brown contusions which are irregularly shaped and measure 0.8 x 0.4 cm and 2 x 1 cm. There is a lighter, poorly defined red brown contusion which measures 0.8 x 0.4 cm in the left lower abdomen.

The right abdomen has the contusions primarily in a line with the umbilicus or in the lower abdomen. On an approximate horizontal line with the umbilicus, are four tan contusions which measure 0.5 cm, 0.4 cm., 0.8 x 0.4 cm and 0.5 cm in greatest dimension. The right lower abdomen exhibits two darker red brown contusions which measure 1 x 0.8 cm and 0.8 x 0.6 cm in greatest dimension.

The mid upper back exhibits two contusions adjacent to the spine. The upper contusion is oval, 0.7 x 0.4 cm and red brown. The lower contusion is light brown, oval and 1 x 0.5 cm.

Cutdown incisions into the back and buttock disclose no further injury except for a single hemorrhagic focus in the subcutaneous fat of the left buttock measuring approximately 0.5 cm but having no cutaneous bruising.

EXTREMITY INJURIES:

The right forearm exhibits two contusions, on light red rounded 0.5 x 0.6 cm. Just distal to that is a large round red contusion which measures 1.2 cm in greatest dimension. There is a minute focal brown contusion over the right lateral wrist.

There is blue discoloration over the thenar eminence bilaterally which exhibits no subcutaneous hemorrhage.

The right anterior tibia, inferior to the point of insertion of the intraosseous catheter, exhibits two red brown contusions. The superior one is irregularly rounded and measures 0.8 x 0.7 cm, the inferior measures 0.5 cm in greatest dimension. The right inner knee exhibits a linear, crusted partially sloughing interrupted abrasion measuring 0.8 x 0.1 cm. The posterior right calf exhibits two crusted sloughing linear abrasions which are almost parallel on an oblique angle across the calf. The measure 1.5 cm in length and 0.4 cm in length. Similar, less crusted abrasions extend along the lateral right leg, from approximately the level of the lower thigh to the ankle and measure 0.4 cm in length, 0.7 cm in length and 0.7 cm in length.

The dorsum of the right foot exhibits a red area of discoloration over the web space between the big toe and the 2nd toe which measures 0.2 cm in greatest dimension. The inner aspect of the right big toe exhibits an area of blue discoloration which measures 0.8 x 0.5 cm. The dorsal surface of

KASSIDY BORTNER

2000-1862A

the left foot along the line of the metatarsal phalangeal joints exhibits tan abrasion which measures 0.2 cm under the 2nd toe, 0.2 cm under the 4th toe, and 0.4 x 0.2 cm between the 4th to 5th toe.

The soles of both feet exhibit tan abrasions distributed apparently randomly across the arch. Examination with a magnifying lens does not show apparent puncture although one of the lesions on the right foot does show slight brown discoloration in the subcutis deep to the abrasion.

The lesions on the left foot tend to be slightly larger and show a distinctly elevated, crusted surface. Some of the larger lesions on the left show a distinct area of central pallor with a darker brown rim. There is a suggestion of pairing in some of the lesions. The left foot lesions number 10-15 and range from 0.2 to 0.5 cm in greatest dimension. Two areas show a linear appearance, measuring 0.5 x 0.2 cm.

The lesions on the sole of the right foot are more uniform in size, averaging 0.2 cm and showing very little eschar with slight red discoloration deep to the lesions. There are 10-15 lesions on the right foot.

VAGINAL AND ANAL REGION:

Examination of these two areas at the time of autopsy do not reveal any injury. The anus is pale and uniform. The vagina exhibits reddish discoloration with lividity. There is no laceration or foreign material identified. The hymen appears slightly irregular but intact.

EXTERNAL EXAMINATION

The body is that of a well developed, slender, but apparently well nourished white toddler appearing approximately the stated age of 21 months. The previously described external bruising and abrasions will not be repeated here.

The following measurements are taken: The body weighs 22.2 pounds (in the 10-25th percentile) and measures 2 feet, 9 inches in length (50th percentile). The head circumference is 47.4 cm (25th-50th percentile), chest circumference 46.3 cm, abdominal circumference 38.5 cm, crown to rump length 53 cm.

Rigor mortis is minimally present. Livor mortis is present over the posterior surfaces.

The head is symmetrical and shows the extensive previously described bruising. The face shows extensive red to purple bruising, some of which has a curvilinear appearance. The head hair is blond, fine, straight approximately 5 inches long, and there appears to be generalized alopecia over the posterior and lateral scalp. The sclerae and conjunctivae are pale and the bulbar conjunctiva of the upper eyelid shows no petechiae. The conjunctiva of the left lower eyelid

shows a single minute petechial hemorrhage. On the right, there is a single darker petechia and a few very light petechiae. The corneas are clear. The irides are blue. The pupils are 4-5 mm and equal. The nose is intact with no palpable fracture. No facial fractures are palpable. The mouth and oral cavity show the described injury. The teeth are present and unremarkable. The external ears show the bruise on the right with lividity but no bruising on the left.

The neck is symmetrical. The bruising has been described. The chest is symmetrical and shows no distinct bruising anteriorly. The breasts are those of an immature female. The abdomen is soft and shows the described bruising.

The arms are symmetrical and show no unusual features. The hands, fingers, and fingernails are unremarkable except that there is a brown keratotic warty lesion on the right index finger, radial surface, which measures 0.4 x 0.4 x 0.2 cm. There is poorly defined red discoloration over the knuckles of the right index and middle finger which show no subcutaneous hemorrhage.

The legs are symmetrical and show the areas of abrasion. The feet show the described pinpoint lesions on the soles. There is a firm tan plantar type wart on the superior aspect of the right great toe.

The external genitalia show no trauma and are those of an immature female. The anus shows no trauma.

The posterior body surfaces are unremarkable except for the described contusions of the upper back.

INTERNAL EXAMINATION

The body is opened with the usual Y-shaped and intermastoidal incisions. The body cavities reveal no adhesions. The following effusions are present: There is a very small amount (less than 5 ml) of blood over the mesentery. There is approximately 6 ml of serous fluid in the pericardial space. The panniculus measures 0.5 cm. in thickness.

HEAD CONTENTS AND CENTRAL NERVOUS SYSTEM: The scalp shows multiple subgaleal contusions, some associated with the scalp contusions seen externally. They are located over the left anterior frontal area, the left superior parietal area, the right superior parietal area, the posterior occiput. The skull exhibits no fractures. There is bilateral, minimally adherent subdural layering over the middle and posterior cranial fossa bilaterally and approximately 20 ml of coagulated subdural hematoma over the superior convexities bilaterally. The brain weighs 1055 grams. There is a small amount of subarachnoid hemorrhage which is most evident on the basilar surfaces of the occipital and cerebellar cortices. The Circle of Willis shows no atherosclerosis and no aneurysms. The meninges are otherwise clear. The cerebral hemispheres

KASSIDY BORTNER

2000-1862A

are symmetrical with mild flattening of the sulci and gyri and no obvious focal lesions grossly. The brain is fixed in formalin for further examination.

A posterior approach to the spinal cord reveals no injury to the posterior neck. Although there is moderate subdural blood in the lumbar region, there is no overlying injury and the cord shows no palpable injury. This may represent blood drained to this level.

The eyes in association with the optic nerve are examined by an approach from the basilar skull. There is focal acute optic nerve hemorrhage. A small amount of vitreous is removed and formalin is introduced to expedite fixation. The eyes are photographed and placed in formalin for fixation and subsequent examination of the retina.

NECK ORGANS: These tissues are dissected after major organs are removed. The deep and superficial muscles of the neck show acute hemorrhage deep to the areas of contusion. There is no hemorrhage in other layers of the muscle. The hyoid bone is intact. The thyroid and cricoid cartilage shows no fractures. The larynx is pink tan and shows no evidence of edema or aspiration. The tongue reveals bitemarks bilaterally over the anterolateral aspect associated with contusion.

CARDIOVASCULAR SYSTEM: The heart weighs 62 grams. The epicardium is smooth and shiny. The coronary arteries follow balanced distribution and show no anomalies. There is no atrial or ventricular septal defect. The foramen ovale is closed. The myocardium is red brown firm and uniform. The chambers are not dilated or hypertrophied. The left and right ventricles are 0.2 and 0.8 cm in thickness respectively. The valves are unremarkable in appearance and have the following measured circumferences: tricuspid valve-6.0 cm, pulmonary valve-3.8 cm, mitral valve-5.0 cm, and aortic valve-3.8 cm. The endocardium, chordae, and papillary muscles are unremarkable.

The aorta follows a normal anatomic pattern and shows a smooth intimal surface. The venae cavae and the great vessels show no identifiable lacerations.

LUNGS: The right and left lungs weigh 125 and 107 grams respectively. The parenchyma shows irregular dark red areas of atelectasis in the upper lobes with a more uniformly congested red purple rubbery appearance to the lower lobes. The tracheobronchial tree shows no blood or aspirated material. The pulmonary vessels are intact and show no emboli.

HEPATOBILLIARY SYSTEM: The liver weighs 450 grams. The capsule is smooth and intact. The parenchyma shows a uniform red brown, slightly congested lobular appearance with no hemorrhage. The gallbladder is intact. It contains 4 ml. of green bile and the mucosa is smooth.

The pancreas is normal in size and shape and has a normal appearing, tan, lobular parenchyma

KASSIDY BORTNER

2000-1862A

with no fat necrosis or hemorrhage.

HEMATOPOIETIC SYSTEM: The spleen weighs 25 grams. The capsule is smooth and intact. The spleen shows a focally congested darker red area in the lower pole, within an otherwise grey pink soft uniform parenchyma.

The thymus gland is normal in size and shape. It weighs 11 grams. The parenchyma is pink/tan and shows rare petechiae on the superficial, anterior surface.

The lymph nodes are grey, soft and unremarkable in appearance. The bone marrow is red brown and unremarkable.

GASTROINTESTINAL SYSTEM: The oropharynx, esophagus, and stomach are intact with no tracheo-esophageal fistulas. The stomach contains 42 ml of tan semi viscid material with strands of mucus. The duodenum, jejunum, ileum, and colon show loops of bowel distended by air with no acute hemorrhage to the bowel. There is a small amount of tan to green soft material in the loops of small intestine with green clay like material in the colon. The root of the mesentery is diffusely hemorrhagic, not distinctly associated with a single vessel and with no distinct laceration. The appendix is identified.

ENDOCRINE SYSTEM: The adrenal glands show well defined yellow cortices and an unremarkable medullae. Together they weigh 6 grams. The thyroid gland is normal in size and shape. The parenchyma shows a red brown lobular appearance with no nodularity. The parathyroid glands are not identified.

GENITOURINARY SYSTEM: The right and left kidneys weigh 35 grams and 37 grams respectively. The renal capsule strips with ease to reveal a smooth red brown moderately congested surface. The cortices are well demarcated and normal in thickness. The medullae and renal papillae are unremarkable. The pelves and collecting system is intact. The ureters are patent and show no lesions. The bladder contains 20 ml of yellow urine. The bladder mucosa is wrinkled and unremarkable.

The cervix, uterus, fallopian tubes and ovaries are present and apparently unremarkable in appearance. An abdominal perineal resection of the pelvic organs shows no distinct injury. There is a slight redundancy to the distal vagina with no hemorrhage or laceration.

MUSCULOSKELETAL SYSTEM: The muscles are well developed. Examination of the multiple cutaneous bruises reveals apparently acute hemorrhage into subcutis and muscle deep to the lesions including over the surface of the right anterior tibia in a location separate and distinct from the intraosseous catheters. The skeleton is well developed and appropriate for age. Fractures or focal trauma are not identifiable grossly due to lack of associated hemorrhage except

KASSIDY BORTNER

1112

2000-1862A

as noted above over the right anterior tibia. The areas noted by X-ray are taken for microscopic examination.

KASSIDY BORTNER

2000-1862A

1113

WORKSHEET

BODY TO OFFICE OF CHIEF MEDICAL EXAMINER BY: Wilson Cooper Funeral Home.

RELEASED TO: Adams Funeral Home.

PERSONAL PROPERTY: None.

IDENTIFICATION: Band around right ankle.

TOXICOLOGY: Blood: Two grey top tubes of peripheral anticoagulated blood, 1 vial of peripheral non-anticoagulated blood; Urine: 1 vial; Vitreous: 1 vial; Liver: 1 small bag; Gastric: 1 small bag. One grey top tube is sent to National Medical Services, Inc. for testing. All of the rest of the specimens are retained at the Office of the Chief Medical Examiner.

LABORATORY TESTING: A small vial of clear vitreous is submitted to Maine General Medical Center for testing. Blood from the heart is submitted for culture.

X-RAYS: A skeletal survey is performed by York Hospital but does not include sufficient views of the skull and no x-rays of the hands or feet. Skull x-rays are taken by the Office of Chief Medical Examiner. X-rays of the hands and feet are taken at Maine General Medical Center, Augusta.

SEROLOGY: DNA card.

HISTOLOGY: Multiple representative sections are taken for microscopic examination. Representative tissue samples are retained at the Office of Chief Medical Examiner.

NEUROPATHOLOGY AFTER FIXATION: The brain is submitted to Dr. William Pendlebury, Neuropathologist, Fletcher Allen Health Care, Burlington, VT for examination.

PRESENT AT AUTOPSY: Adam Rice, Autopsy Supervisor, Office of Chief Medical Examiner; Sgt. Stephen Drake and David Muniec, Maine State Police Crime Laboratory; Detective Eric Baker, Maine State Police, CID I.

PHOTOGRAPHS: Office of Chief Medical Examiner, Detective Eric Baker.

DIAGRAMS: Yes (7 plus growth charts).

CERTIFIED BY: Margaret Greenwald, MD

KASSIDY BORTNER

2000-1862A

MICROSCOPIC EXAMINATION

SUBDURAL BLOOD CLOT (2 sections): The sections consist of clotted blood with fragments of bone and fibrous tissue. The blood clot consists of intact erythrocytes mixed, for the most part, with a small number of leucocytes and a few strands of fibrin. There is early lines of Zahn and reactive inflammation only along the edges in the sections examined.

HEART (2 sections): Sections from both right and left ventricle are examined. There is no acute inflammation or hemorrhage. There is no significant histopathology.

LUNGS (5 sections + 4 additional osmium stained sections, multiple levels) : The sections of lung exhibit a fairly well aerated parenchyma. The pulmonary vessels show empty rounded 'cutouts' in the midst of marked congestion. There are no bone marrow elements associated with the cutouts. The alveoli rarely show a few scattered macrophages or sloughed bronchial epithelial cells, but most of the sections of larger and smaller bronchi exhibit intact epithelium with no inflammation, minimal autolysis and no evidence of aspiration. There is no acute or chronic intra-alveolar inflammation. Osmium stain of formalin fixed sections of lung confirm the presence of extensive fat emboli in all of the sections examined.

LIVER (1 section): The hepatic architecture is intact. There is no evidence of steatosis, fibrosis, inflammation or hemorrhage.

SPLEEN (1 section): There is moderate sinusoidal congestion. The follicles show an unremarkable architecture with no inflammation or malignancy. The capsule is intact.

KIDNEYS (2 sections): The tubular and glomerular vessels are moderately to markedly congested. No obvious fat globules are seen in the tubular vessels, but there is a suggestion in one of the sections of empty spaces in glomerular capillary loops. Osmium stain shows rare fat emboli in glomerular vessels, but prominent emboli in vessels of the renal hilum.

ADRENAL GLANDS (2 sections): The architecture is intact. There is no significant histopathology.

THYMUS (1 sections): The section exhibits a normal lobular structure with a prominent cortex consisting primarily of small, mature lymphocytes. The medulla contains well developed Hassall's corpuscles. There is no evidence of malignancy. Petechiae are not evident in the section examined.

DIAPHRAGM (1 section): The section shows muscle bundles, variably oriented with no inflammation or significant histopathology.

TONGUE (1 section, 2 levels): The sections exhibit minimally keratinized squamous epithelium over thick skeletal muscle. In the sections examined, there is mild desquamation of the epithelium without significant inflammation. The areas of contusion are not demonstrated in the sections examined.

GASTROINTESTINAL SYSTEM(7 sections): A section of cardioesophageal junction exhibits intact squamous mucosa. The gastric mucosa exhibits moderate autolysis of the surface epithelium. The lamina propria contains intermittent lymphoid follicles comprised of round cells with an occasional neutrophil. The deeper portions of the gastric glands are retained and are unremarkable

Four sections of small intestine are examined. In one section, the serosal (visceral peritoneum) surface shows no significant inflammation, congestion or hemorrhage. The muscularis is unremarkable and there is moderate desquamation of relatively preserved mucosal epithelium with unremarkable secretory glands.

In a second section, there is marked vascular congestion of vessels in the lamina propria and muscularis. In a third section, there is acute hemorrhage into the lamina propria and muscularis. Where the hemorrhage is prominent and separating the layers of intestine, there is early reactive inflammation around the edges of the blood in the tissue. Both of these two sections show variable mild edema of the visceral peritoneum. While the villi in these two sections are autolyzed, the glands at the base of the villi are intact. There is mild acute submucosal inflammation and scattered lymphoid follicles.

The fourth section examined exhibits a large area of acute hemorrhage of the serosal surface (visceral peritoneum) extending through the muscularis and the lamina. There is edema and reactive inflammation including migration of granulocytes around the periphery of the hemorrhage. The blood within the area of injury shows prominent lines of Zahn. The mucosal surface is relatively intact but autolyzed. The hemorrhage is most prominent in the outer layers of the intestine, where there is a prominent neutrophilic inflammation, fibrin and platelet deposition and early necrosis of neutrophils. All of the erythrocytes appear intact.

A section of colon shows marked acute congestion of the vessels in the serosa, with no significant edema or inflammation. The inner layers of the colon show mild autolysis of the mucosa, but no other significant histopathology.

A section of the anal rectal verge is examined. The mucosa varies from squamous to the typical columnar epithelium of the large intestine. There is no significant histopathology.

MESENTERY (4 sections) : Sections of fibroadipose tissue taken from the mesentery show hemorrhage of variable intensity infiltrating through the fat and in and around lymph nodes,

KASSIDY BORTNER

2000-1862A

nerves and ganglions, and larger vessels. When the hemorrhage consists of a large collection of blood, lines of Zahn are apparent. The lymph nodes in the affected areas show a normal architecture of abdominal lymph nodes with some reactive follicles. Along the periphery of the more intense areas of hemorrhage, there is early reactive inflammation with presence of lymphocytes and granulocytes.

LYMPH NODE (1 section) An individual lymph node, not associated with the mesentery is examined. The capsule is intact. There is marked acute congestion with focal hemorrhage into the parenchyma. The follicles are reactive. There is no malignancy.

VAGINA (1 section): The section exhibits squamous mucosa overlying fibrous and muscular layers. There are prominent folds. The external areas show moderate cornified cells overlying basal cells. In the portions of the vagina closest to the cervix, the mucosa is thinner and there is desquamation of the superficial squames. Focal subacute inflammation is present in the lamina propria. There is no evidence of hemorrhage or necrosis.

PANCREAS (2 sections): The architecture is intact. There is moderate acute congestion of adjacent vessels. There is no evidence of fat necrosis, inflammation or malignancy. Pancreatic islets are present and are uniformly distributed in the sections examined.

BONE MARROW (1 section): A section of vertebral bone marrow shows a normocellular marrow. The myeloid to erythroid ratio is approximately 3:1 or 4:1 and the maturation sequence is unremarkable. Megakaryocytes are present in adequate numbers. There is no evidence of malignancy. The bone and cartilage elements are intact and show normally progressive endochondral ossification.

LEFT EYE AND OPTIC NERVE (4 sections + 2 iron stains): In the left eye, there is focal acute hemorrhage in the artifactually fragmented retinal sections. Iron stain is negative. There is acute subdural and subarachnoid hemorrhage more prominent proximally as the nerve exits the eye, but also noted in some of the distal segments. The red cells are intact. There is no reactive inflammation. While hemosiderin is not seen on H & E stain, Iron stain reveals slight to 1+ iron both intracellular and extracellular.

RIGHT EYE AND OPTIC NERVE (4 sections + 2 iron stains): The sections consist of the posterior eye and optic nerve. There is extensive artifactual fragmentation of the retina. There is mild acute congestion of the retinal vessels. Small foci of acute hemorrhage are present in the retina. Iron stain is negative. There is acute subdural hemorrhage around the optic nerve as it exits the eye with less hemorrhage distally. The erythrocytes in the acute hemorrhage are intact. There is no reactive inflammation. Iron stain of the eye and optic nerve show slight positivity involving both intracellular and extracellular iron.

KASSIDY BORTNER

2000-1862A

BRUISES AND OTHER LESIONS OF SKIN AND SCALP:

Two bruises from mid back (2 sections with 3 levels each+ Iron stain): The sections consist of skin and subcutaneous tissue. The stratified squamous epithelium is intact and without hemorrhage or inflammation. There is slight acute hemorrhage into the subcutaneous adipose. There is no reactive inflammation. Iron stain reveals no significant positivity.

Posterior occipital subgaleal (1 section, 8 levels + Iron stain): Multiple sections of fibrous and fibroadipose tissue taken from the galea. There are hair follicles present. There is acute hemorrhage in both adipose and fibrous tissue with no reactive inflammation. Iron stain reveals a slight amount of intracellular and extracellular iron in areas not directly adjacent to the acute hemorrhage.

Right posterior occipital subgaleal (1 section, 2 levels + Iron stain): The sections show focal acute hemorrhage with more prominent subacute reactive inflammation with localized fat necrosis, rare neutrophils and prominent macrophages and plasma cells. Iron stain reveals slight intracellular and extracellular iron.

Superior occipital area (1 section, 2 levels + Iron stain): Fibroadipose tissue with hair and sebaceous glands which exhibits acute hemorrhage infiltrating through both adipose and fibrous tissue. There is early reactive inflammation with presence of both neutrophils and macrophages. The erythrocytes are intact. There is rare intracellular iron.

Left buttock hemorrhagic fat (1 section + Iron stain) : The section consists of skin and subcutis. The keratinized squamous epithelium is intact. The prominent feature is subacute to chronic inflammation with fibrosis in the deep subcutis. Golden brown intracellular pigment in macrophages is apparent on H & E stain. Rare acute hemorrhage is noted. Iron stain reveals 2-3 + (moderate) intracellular and extracellular positivity.

Right shoulder (2 sections, 2 levels each + Iron stain): The sections consist of skin and subcutis with intact keratinized stratified squamous epithelium. There is no hemorrhage or inflammation in the dermis or subcutis identified on multiple sections. Iron stains reveal rare extracellular clumps which may be artifact.

Subcutaneous tissue, left mandible (1 section, 3 levels + Iron stain): The section is fibroadipose tissue with a prominent acute hemorrhage. There is prominent acute reaction with presence of multiple neutrophils, lymphocytes and macrophages. Fibrin deposition is apparent. Iron stain shows rare intracellular iron, not directly adjacent to the area of hemorrhage.

Subcutaneous tissue, chin (1 section, 3 levels + Iron stain): The section shows

KASSIDY BORTNER

2000-1862A

fibroadipose tissue with acute hemorrhage tracking along fibrous bands and through adipose tissue. There is prominent acute inflammatory reaction, consisting predominantly of neutrophilic response with some lymphocytes and macrophages. Fibrin deposition is present. Iron stain shows rare positivity.

Subcutaneous tissue, right mandible(salivary gland) (4sections + Iron stain) The sections show the submandibular salivary gland with associated fibroadipose and fibrovascular connective tissue. There is acute hemorrhage surrounding the gland, but not extending into the tissue of the gland itself. There is focal acute inflammation in the submandibular gland with some amorphous material in ducts. The hemorrhage is predominantly acute, without significant reaction, but in at least one area there is reactive inflammation with a prominent neutrophilic reaction, and a few lymphocytes and macrophages. There is evidence of fibrin deposition and necrosis of adipocytes and collagen. Iron stain shows no significant positivity.

Mucosa of lower lip (2 sections, 3 levels + Iron stain): The sections show non keratinized stratified squamous epithelium and underlying dermis. In one of the sections, there is focal denuding of the full thickness of the mucosa with necrosis of the underlying collagen and residual fragments of the squamous epithelium. There is acute inflammation in the dermis under the abraded area. There are also multiple foci of acute hemorrhage in the dermis. The inflammation and hemorrhage track through the dermis and there is acanthosis in the adjacent squamous epithelium which except for a single focus of intraepithelial hemorrhage, associated with acute inflammation, remains intact. Some of the acute inflammation extends into the underlying sebaceous gland. Iron stain reveals no significant positivity in the sections examined.

Frenulum (Lower lip) (1 section, 8 levels + Iron stain): The sections reveal non keratinized squamous epithelium and underlying fibromuscular and fibrovascular tissue. Along the both edges of the sections the muscle bundles are prominent and the fibrous tissue is relatively dense. In the center of the section, there is a clear change with looser connective tissue in the deeper dermis, apparent atrophy of muscles and a hypercellular, vascular area of reparative tissue. The area of ulceration does not show on the section examined. There is focal acute hemorrhage into the superficial compact lamina propria (in the center of the section) with slightly more hemorrhage in the loose connective tissue of the deep dermis. The erythrocytes are intact. There is no significant reactive inflammation. The muscle bundles show no significant abnormality. Iron stain reveals no significant positivity.

Mucosa of left cheek (1 section, 9 levels + Iron stain): The section consists of non keratinized stratified epithelium over connective tissue. There is focal denuding of the epithelium with underlying acute reactive inflammation, and necrosis. Muscle bundles in

KASSIDY BORTNER

2000-1862A

the deeper tissue shows areas of prominent atrophy, regeneration and fibrosis. There is no significant hemorrhage. There is some artifact in the Iron stain but no significant positivity.

Anterior frontal subgaleal (1 section + Iron stain): The section consists of fibrovascular and fibroadipose tissue. There is acute hemorrhage tracking through fibrous and adipose tissue. The erythrocytes are intact. There is focal edema. There is acute reactive inflammation with collections of neutrophils, lymphocytes and macrophages. Minute fragments of bone are along one edge. Within the areas of fibrous tissue, there are areas where the collagen fibers are discontinuous, there is looser fibrosis and macrophages. There are both plump macrophages and elongated fibroblasts with identifiable golden brown pigment. Iron stain reveals 3-4+ iron, both intra- and extracellular in nature, primarily located in areas of recent and healing fibrous tissue and only slight in the areas of new hemorrhage.

Right superior subgaleal (1 section, 3 levels + Iron stain): The sections show fibroadipose tissue with hair follicles. There are multiple stages of injury and healing in the sections. There are areas of healing fibrosis with residual inflammation and early collagen formation. Golden brown pigment is apparent on H & E stain with in bands of fibrosis. There are congested thin walled vessels in these fibrous bands with some acute extravasation of erythrocytes into adjacent tissue. There are also areas in the adipose tissue, not associated with the healing, which show acute hemorrhage with early reactive inflammation, fibrin deposition and edema. Iron stain reveals 3-4+ iron, primarily (but not exclusively) intracellular.

Left superior subgaleal (1 section, 3 levels + Iron stain): The section consists of fibroadipose and fibrovascular tissue with multiple hair follicles. There is an area of acute hemorrhage, acute reactive inflammation, fibrin deposition and early basophilic tissue necrosis. The acute hemorrhage tracks through the adipose tissue. The predominant cell is the neutrophil with a few lymphocytes and plasma cells. Iron stain reveals no significant positivity.

Cassette labeled Left supraorbital (No tissue identifiable in cassette after processing)

Right supraorbital (1 section, 11 levels + Iron stain): The section consists of a thick layer of fibrovascular tissue with underlying fibroadipose. There are small fragments of bone along one edge of the tissue. On the opposite edge of the fibrovascular tissue, there is a small focus of prominent vessels where the endothelial cells are plump and there is deposition of golden brown pigment. In another area of adipose tissue, is a focus of acute hemorrhage with early reactive inflammation and fibrin deposition. Iron stain reveals 1-2+ positivity in the area of fibrosis. No significant iron stain positivity is seen in the area

KASSIDY BORTNER

2000-1862A

of acute hemorrhage.

2 Bruises, right forearm (2 sections, 3 levels + Iron stains): The sections consist of skin and subcutis with unremarkable keratinized stratified squamous epithelium. In the subcutaneous fat, acute hemorrhage infiltrates along the fibrous bands and into the adipose. The erythrocytes are intact. There is reactive inflammation which is slightly more prominent in one of the sections, but present in both. The inflammatory cells are macrophages, lymphocytes and neutrophils and there is fibrin deposition and edema in the deeper levels. Iron stain reveals no significant positivity.

2 Bruises, right anterior tibia (2 sections, 4 levels + Iron stains): Two sections of skin with subcutis are examined. In both sections, the keratinized stratified squamous epithelium is intact and the underlying dermis exhibits no injury. There is acute hemorrhage focally into the deeper adipose tissue of the subcutis in both sections. In the first level, there is similar acute reactive inflammation in both sections with intact erythrocytes, acute inflammatory cells and fibrin deposition. In the additional levels, one of the sections is consistent throughout, the second section shows more slightly more organization of the inflammatory process with presence of fibroblasts and more prominent macrophages. Iron stain in the slide shows rare intracellular positivity in area of subacute inflammation only.

Right 3rd finger, distal phalanx (1 section, multiple levels + Iron stain) The section consists of skin with underlying dermis. The keratinized stratified squamous epithelium is intact. There is focal acute hemorrhage into fibrovascular tissue of dermis with minimal acute inflammatory reaction. Iron stain reveals no significant positivity.

Wart, right 2nd finger (1 section, 2 levels): The section consists of skin exhibiting a circumscribed papillomatous lesion. The epithelium shows acanthosis, papillomatosis, hyperkeratosis and parakeratosis. The rete ridges shows the characteristic elongation and point to the center of the lesion. There are large vacuolated cells in the upper stratum malpighii and the granular layer. The nuclei of these cells are round, basophilic and surrounded by a clear zone. The keratotic surface is partially abraded, with focal acute hemorrhage and inflammation.

Left foot (2 sections, 2 levels + Iron) The section consist of markedly keratotic skin. The keratinized layer is intact directly adjacent to the epidermis, however there are two foci of acute inflammation (neutrophils) and necrosis within the superficial layers of keratin, consistent with a small scab. The underlying squamous epithelium shows minimal change with slight acanthosis and elongation of the rete ridges directly deep to the lesion. There is edema and hypercellularity in the superficial dermis surrounding the rete ridges. Cells appear predominantly macrophages consistent with reparative response. Iron stain reveals no significant positivity.

Right foot (3 sections + Iron stain): The sections show markedly keratotic skin. The deeper layers of keratin are intact but within the superficial layers, there are two foci of disruption with basophilic necrosis and acute inflammation consistent with a scab. Iron stain reveals no significant positivity.

FRACTURES WITH CONTROLS:

Left tibia (2 sections): There are two sections of bone which represent a cross section of the tibia through the proximal diaphysis. Along one edge is a thick layer of cartilage. There is laceration, acute hemorrhage and early reactive inflammation with a few neutrophils and macrophages migrating to the area. This is somewhat difficult to see because fibroblastic proliferation and subperiosteal bone formation is also very active. Endochondral bone formation is present but minimal. A few areas of acute hemorrhage, with fibrin deposition are noted throughout the medulla in these sections. Necrotic bone is present along an area of separation in the marrow. Longitudinal sections reveal multiple large foci of acute hemorrhage with some fibroblastic proliferation in otherwise relatively normal appearing bone marrow. Subperiosteal fibrosis with new bone formation including presence of woven bone extends uniformly along both sides of the longitudinal section. Remote injury, remodeling stage with re-injury of acute fracture, inflammatory stage.

Right tibia (1 section, 3 additional levels and two longitudinal sections): A single cross section through the proximal diaphysis of the bone shows acute hemorrhage, fibrin deposition, acute inflammation and focal fat necrosis. Trabecular bone appears focally necrotic with associated reactive acute inflammation. The periosteum is active but appears normal for the location of the section. Elements of normal marrow are seen in areas where fibrin deposition is not identified. The longitudinal sections are very vascular with large arteries and veins traversing the cortex and identified in the marrow. Areas of acute hemorrhage with some fibrin deposition are noted in the marrow and a localized area of acute hemorrhage is present in fibrovascular soft tissue overlying the bone. Determination of underlying injury to bone is difficult due to intraosseous catheter placement.

Right second metacarpal (2 sections): The sections show metacarpal with a recent fracture. There is prominent subperiosteal callous with fibrovascular proliferation and new bone formation. The callous has not yet enveloped the fracture ends. Reparative stage.

Left second metacarpal (2 sections): These sections taken as controls show metacarpal with no injury. The periosteum is tightly applied to the cortical bone. The marrow is fatty and congested without acute hemorrhage, inflammation or necrosis. Normal bone.

Left ulna (1 section): A section through the area of injury shows a prominent subperiosteal callous. Fibrovascular proliferation and new bone formation predominate. Early maturation of the new woven bone to lamellar bone can be identified especially with polarization. Fracture in late reparative to remodeling stage.

Right ulna (1 section): A section through the opposite long bone reveals prominent subperiosteal callous. Fibrovascular proliferation and new bone formation are also present and prominent in this section. Maturation of the new woven bone to lamellar bone can be identified. Fracture in late reparative to remodeling stage.


MICROSCOPIC DIAGNOSES:

1. Acute subdural hematoma with focal iron positivity.
2. Pulmonary fat emboli, diffuse.
3. Recent acute hemorrhage with early reactive inflammation in sections of small intestine and mesentery.
4. Acute retinal and optic nerve hemorrhage, bilateral with foci of intracellular and extracellular iron (old hemosiderin) in both optic nerves.
5. Acute contusions with no identifiable reactive inflammation in sections of skin from mid back and right third finger.
6. Acute contusion with no reactive inflammation identifiable, but slight iron positivity (old hemosiderin) in section from posterior subgaleal scalp.
7. Right posterior occipital scalp, recent contusion with subacute reactive inflammation and slight intra and extra cellular iron.
8. Superior occipital scalp, recent contusion with reactive inflammation and rare intracellular iron.
9. Right superior scalp with recent contusion and non contiguous areas in the section which show remote reparative changes including 3-4 + hemosiderin.
10. Left superior scalp with recent contusion.
11. Right supraorbital scalp with recent contusion and areas reparative change with 2+ hemosiderin in the areas of fibrosis.
12. Left buttock with recent and remote healing contusions (Moderate, 2-3 + hemosiderin).
13. Right shoulder with no obvious injury on microscopic examination.
14. Recent contusion with reactive inflammation, left mandible. Rare intracellular iron is noncontiguous areas of section.
15. Recent contusion with reactive inflammation, chin. Rare iron positivity.
16. Contusion with early reactive inflammation, right mandible area.
17. Acute inflammation in sections of submandibular salivary gland.
18. Recent denudation of mucosa and underlying contusion, mucosa of lower lip.
19. Frenulum (upper lip) with focal acute contusion and areas of reparative change and

KASSIDY BORTNER

2000-1862A

- muscular atrophy.
20. Recent denudation of buccal mucosa of left cheek.
 21. Skeletal muscle atrophy, fibrosis and regeneration in section of left cheek.
 22. Right forearm (2 lesions) showing recent contusions with reactive inflammation.
 23. Right anterior tibia (2 lesions) showing recent and resolving contusions with rare hemosiderin.
 24. Verruca vulgaris, right second finger.
 25. Plantar surfaces of both feet showing minute areas of superficial reparative changes (focal edema and hypercellularity) in epidermis and recent eschars.
 26. Fracture of left tibia, remodeling stage with area of re-injury in inflammatory stage.
 27. Recent fractures of ulnar bones, bilateral, Late reparative to Early remodeling stage.
 28. Recent fracture of right 2nd metacarpal, Reparative stage.



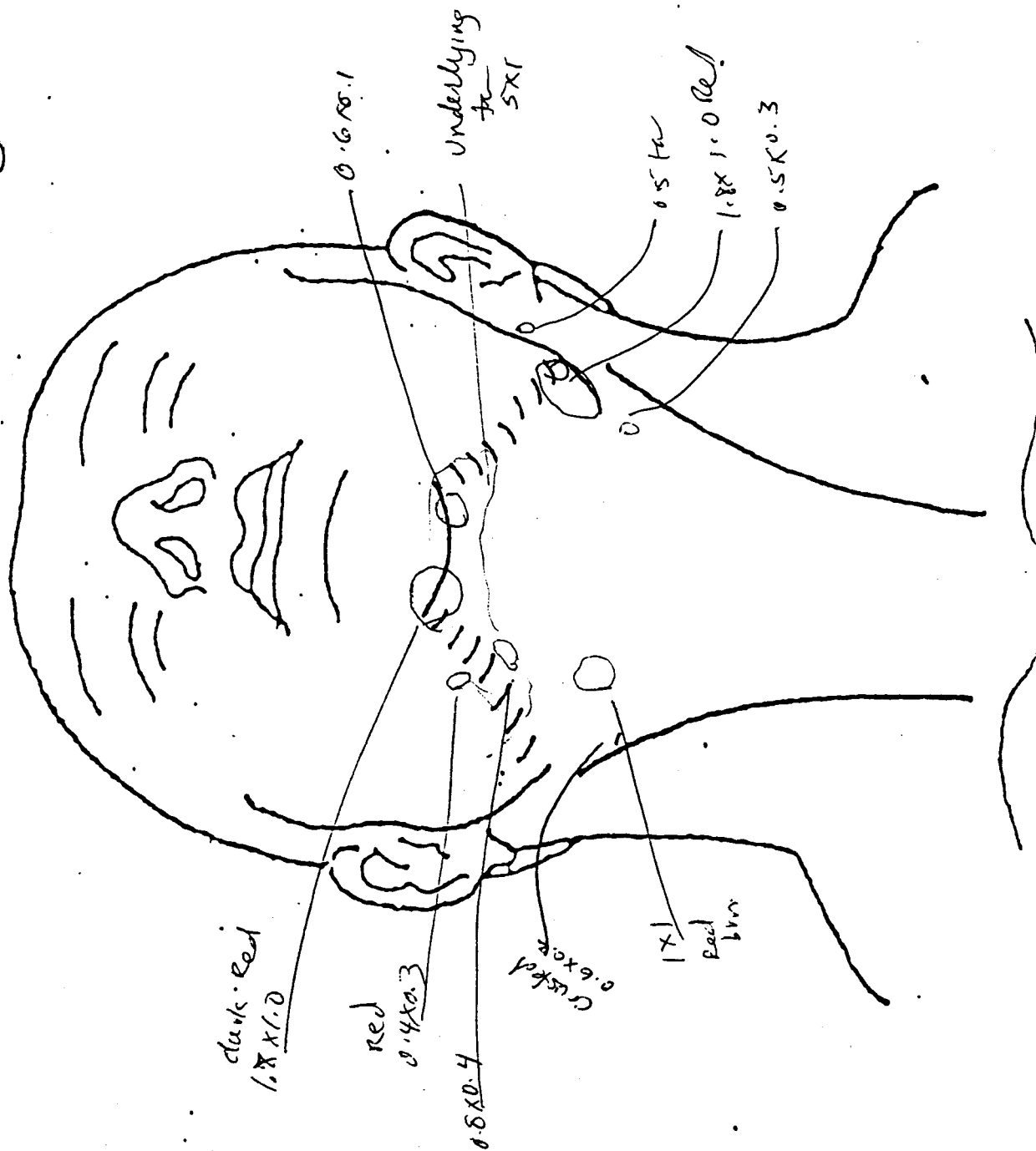
Margaret Greenwald, MD
April 8, 2001

Age _____ Sex _____ Race _____ Date 10 _____ Time _____



6

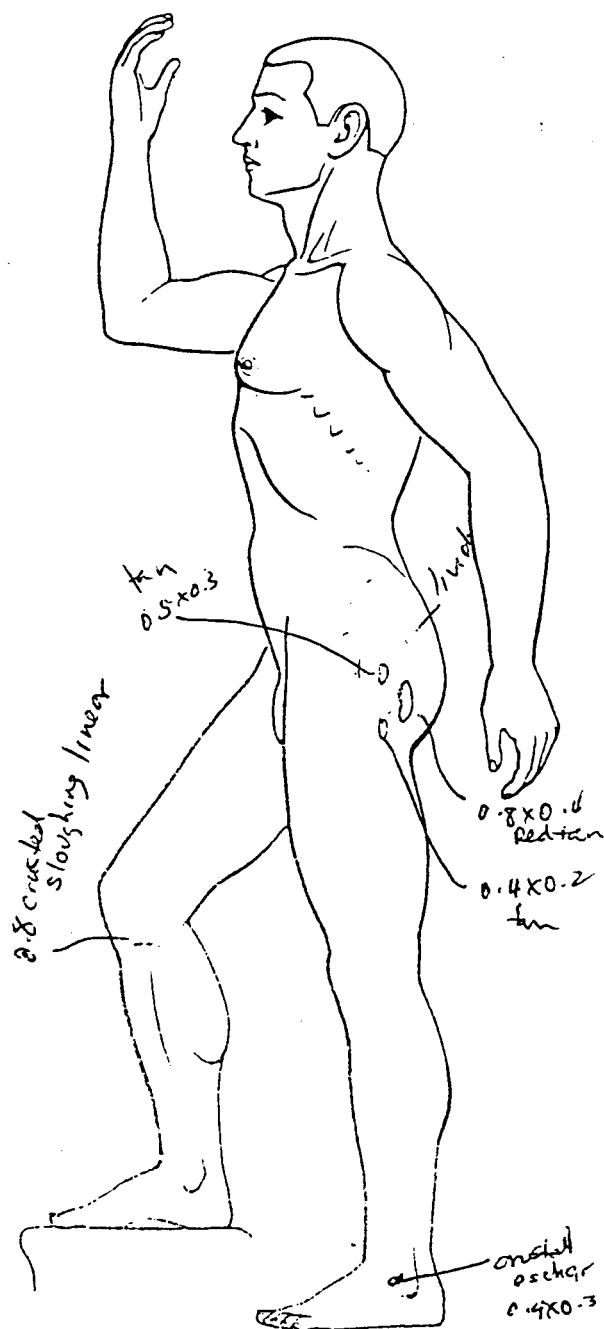
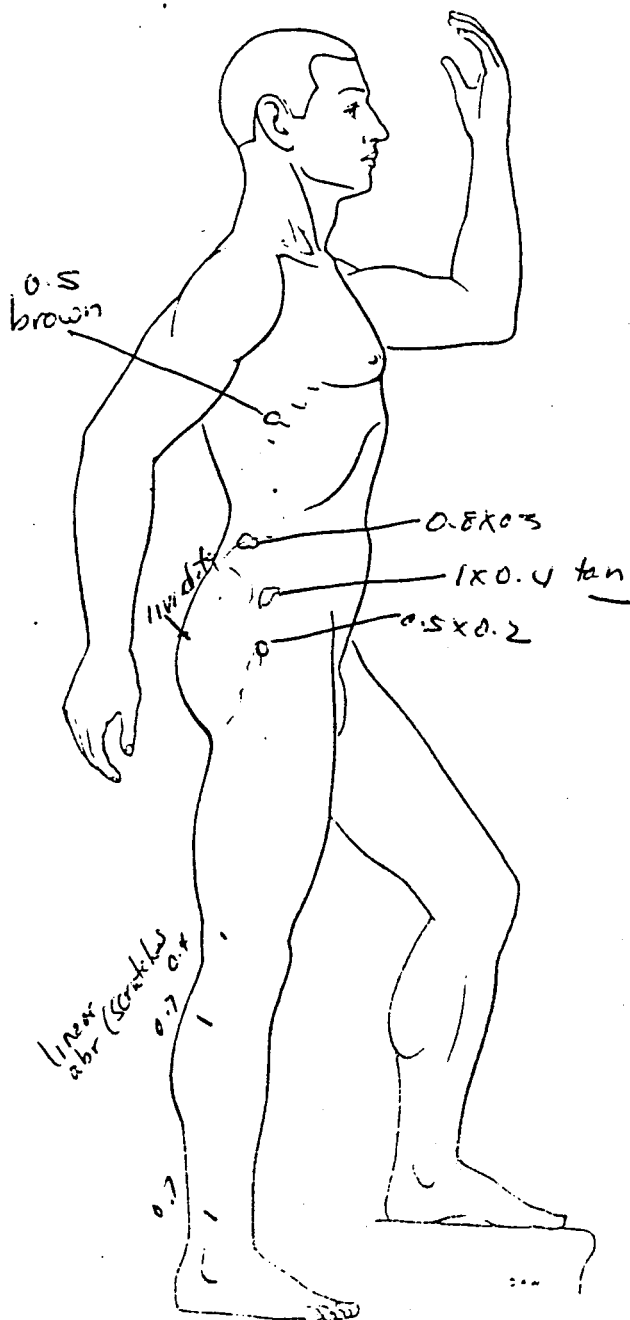
2000-182A
Kassidy
Bohner



5

CASE NO. 2000-1862A NAME Kassidy Butler

1126



Kassidy
Bothe
2000 1862A

1128

10¹⁵ labia
seal

red brn
0.7x0.4

1x0.3 light brown

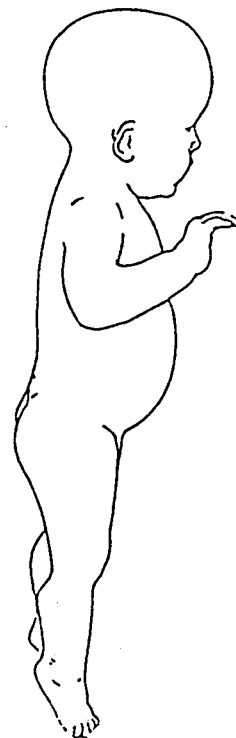

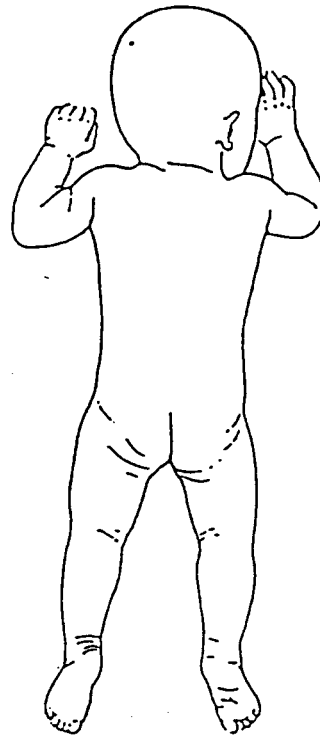
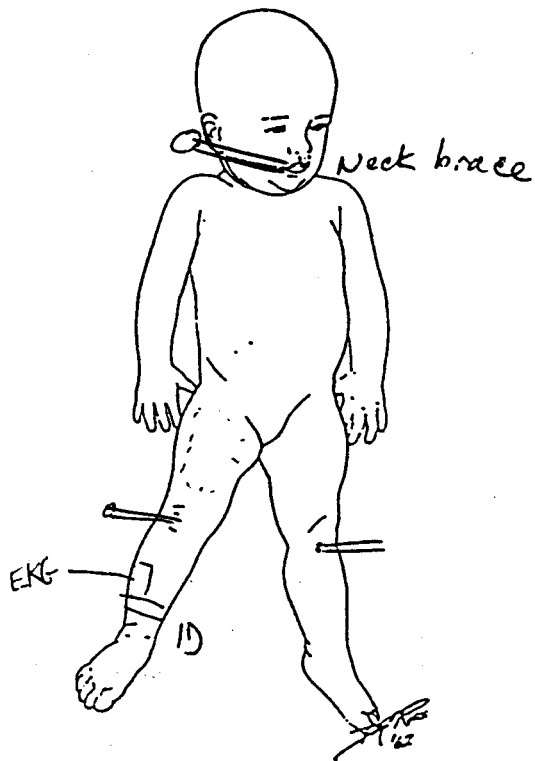
0.5x0.6 H red
Kord
red 1.2x1.1

bin

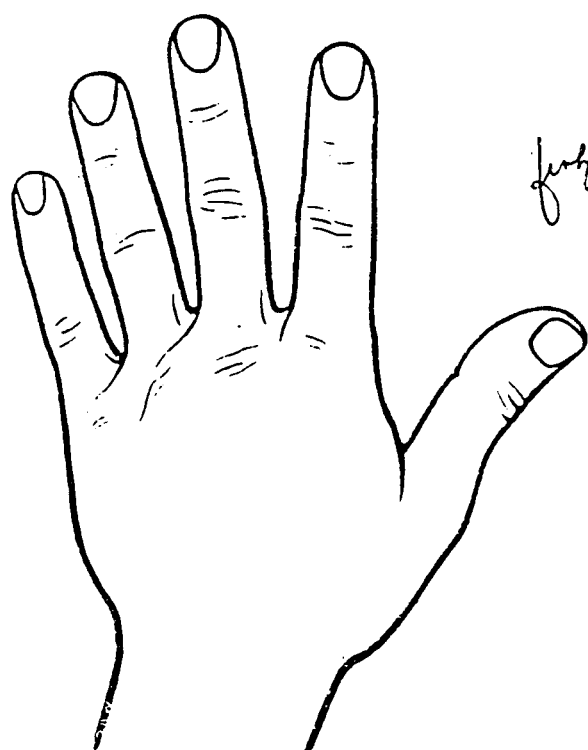0.5x0.2 crusty
H/1
0.5x0.2 crusty
not in 51-mw
pinkish
white

0.5x0.2 crusty

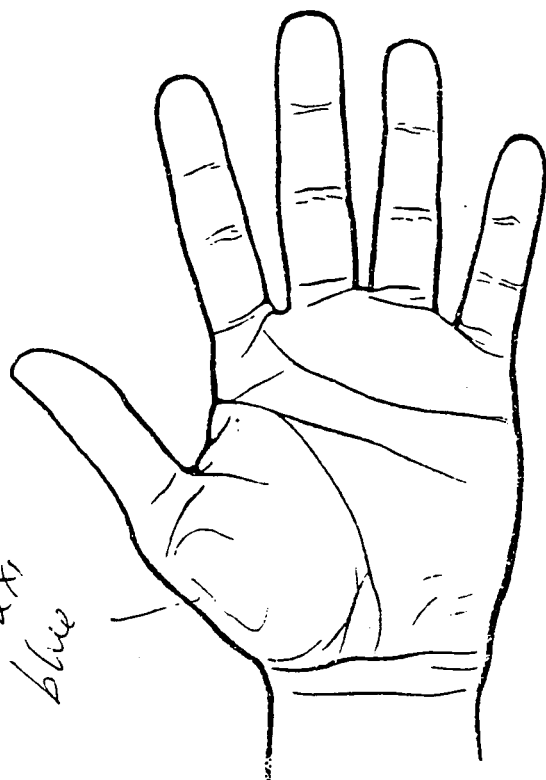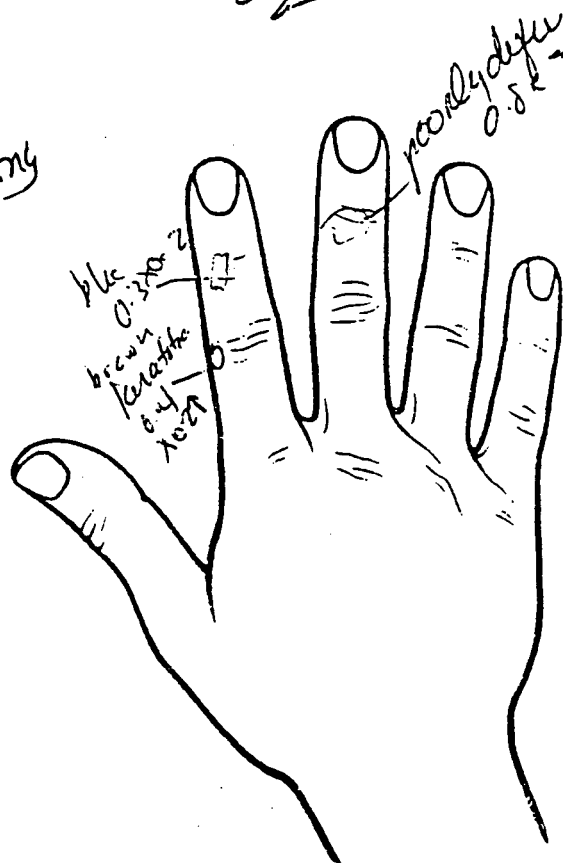1.5
0.4
crustiness
510.5
0.4
511.0
Amput



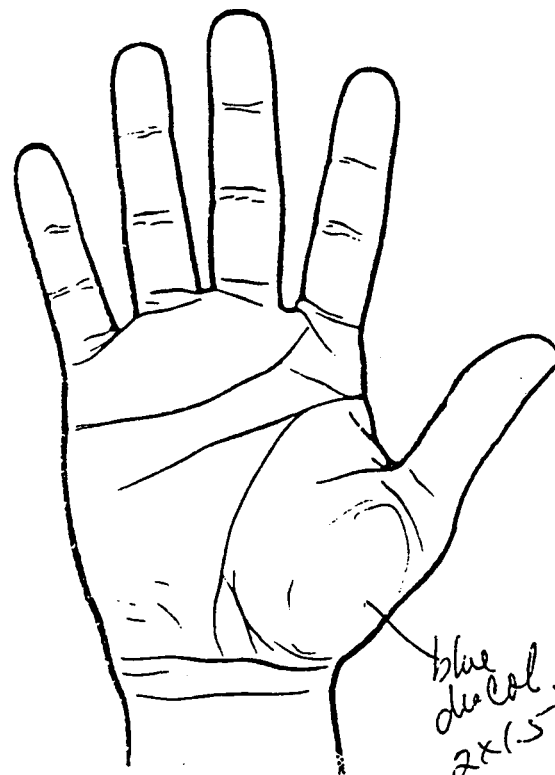
CASE NO. 2000-18624 NAME Kassidy Baxner

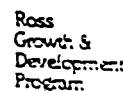


*fingernails long
dirt*



*2x,
blue*



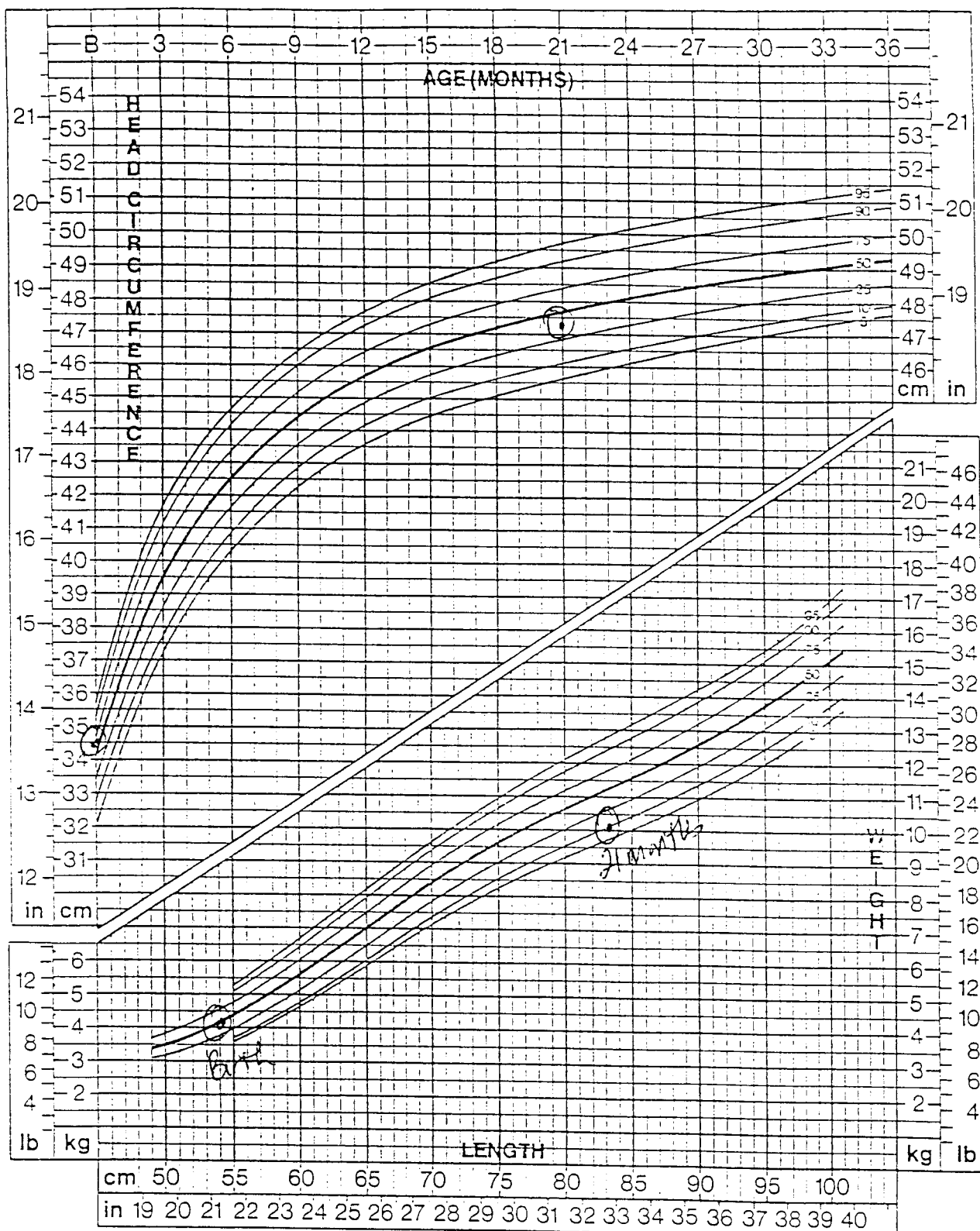


GIRLS: BIRTH TO 36 MONTHS
PHYSICAL GROWTH
NCHS PERCENTILES*

NAME _____

1132

RECORD # _____



* Adapted from: Hamill PVV, Drizel TA, Johnson CL, Reed RB, Roche AF, Moore WM: Physical growth: National Center for Health Statistics percentiles. AM J CLIN NUTR 32 607-629, 1979. Data from the Fels Longitudinal Study. Wright State University School of Medicine, Yellow Springs, Ohio.

© 1987 Ross Laboratories


| DATE | AGE | LENGTH | WEIGHT | HEAD CIRC | COMMENT |
|------|-----|--------|--------|-----------|---------|
| | | | | | |
| | | | | | |
| | | | | | |
| | | | | | |
| | | | | | |
| | | | | | |
| | | | | | |
| | | | | | |
| | | | | | |

SIMILAC® Infant Formulas
in vivo performance
closest to mother's milk

ISOMIL® Soy Protein Formulas
When the baby can't take milk


ADVANCE® Nutritional Beverage With Iron
Instead of 2% lowfat milk

ROSS LABORATORIES
12101 S. C. 4388
CINCINNATI, OHIO 45224



1133

FLETCHER ALLEN HEALTH CARE
BURLINGTON, VT



NAME Cassidy Bortner

AUTOPSY NO. XE00-45
Maine Medical Examiner # 2000-1862A
Pathologist: Margaret Greenwald, MD

NEUROPATHOLOGY LABORATORY

MICROSCOPIC DESCRIPTION
(01/17/01)

LEFT INFERIOR FRONTAL CORTEX: Some of the neurons of the cortical ribbon display ischemic neuronal necrosis characterized by cell body shrinkage, pyknotic nucleus and eosinophilic tinge of the cytoplasm.

RIGHT TEMPORAL LOBE: Subarachnoid hemorrhage is present diffusely throughout the leptomeninges. As with the frontal cortex, neuronal ischemia is noted to a mild degree in the cortex.

LEFT BASAL GANGLIA: No additional significant histopathologic features.

LEFT HIPPOCAMPUS: No additional significant histopathologic features.

GENU OF CORPUS CALLOSUM: No additional significant histopathologic features.

OPTIC CHIASM: No additional significant histopathologic features.

MIDBRAIN: No additional significant histopathologic features.

PONS: No additional significant histopathologic features.

MEDULLA: No additional significant histopathologic features.


SPINAL CORD (3 levels): No additional significant histopathologic features.

SUBDURAL: There is an acute hemorrhagic collection underlying the dura. There is no evidence of membrane formation. Iron stain discloses minimal focal positive staining at the interface between the dura and the hemorrhagic collection.

Cassidy Bortner

DIAGNOSIS:

1. Traumatic encephalopathy with:
 - A. Subdural hemorrhage, acute, posterior aspect of cerebral hemispheres associated with minimal focal positive iron staining.
 - B. Subarachnoid hemorrhage, acute, area of right temporal lobe inferiorly.
 - C. Cerebral edema characterized by sulcal obliteration and gyral flattening.
 - D. Hemorrhage, acute, bilateral optic nerves and rostral optic chiasm.
 - E. Anoxic changes, acute, neocortex.


William W. Pendlebury, M.D.
Neuropathologist

FLETCHER ALLEN HEALTH CARE
BURLINGTON, VT

1135

NAME Cassidy Bortner

AUTOPSY NO. XE00-45
Maine Medical Examiner # 2000-1862A
Pathologist: Margaret Greenwald, MD

NEUROPATHOLOGY LABORATORY

MACROSCOPIC DESCRIPTION


(12/01/00)

The brain weight following fixation is 1030 grams. A segment of dorsal cerebral dura is available for examination and shows no evidence of significant epidural hemorrhage. There is a 2 x 3 cm subdural hemorrhagic collection overlying the right posterior quadrant of the cerebral hemispheres. The superior sagittal sinus is patent. Gross external examination of the cerebral hemispheres reveals the leptomeninges to be thin and delicate and show evidence of significant subarachnoid hemorrhage that is 4 x 4 cm and involves the inferior aspect of the right temporal lobe. The gyral pattern is of normal anatomic configuration. The sulci are obliterated, associated with gyral flattening. The cortical veins overlying the dorsal aspect of the posterior cerebral hemisphere are prominent. The vessels at the base of the brain show no arteriosclerosis and are widely patent throughout. No congenital aneurysms are noted. There is no evidence of uncal or cerebellar herniation. There is a tiny hemorrhagic focus overlying both optic nerves just rostral to the chiasm. Gross external examination of the cerebellum and brainstem reveals no abnormalities.

Multiple coronal sections of the cerebral hemisphere reveal the grey and white matter structures to be of normal configuration. The ventricular system is symmetrical and slit-like. The mammillary bodies are of normal size, color and consistency. Serial sections of the cerebellum and brainstem reveal no significant gross abnormalities.

Sections taken:

| | |
|----------------------------------|-----------------------------|
| [x] Left inferior frontal cortex | [x] Midbrain |
| [x] Spinal cord (3 levels) | [x] Pons |
| [x] Subdural | [x] Medulla |
| [x] Right temporal lobe | [x] Genu of corpus callosum |
| [x] Left basal ganglia | [x] Chiasm |


William W. Pendlebury, M.D.
Neuropathologist

Edwin W. Naylor, PhD, MPH
Laboratory Director

Neo Gen Screening
PO Box 219
Bridgeville, PA 15017

Date of Report
11/23/2000

(412) 220-2300 Phone
(412) 220-0784 Fax

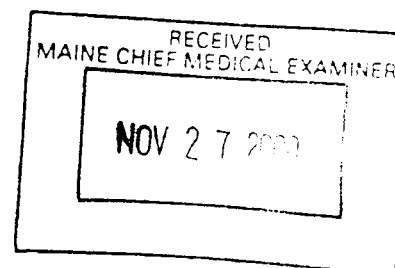
Page 1 of 1

Date Collected: 00/00/0000 Date Recvd: 11/20/2000 Birth Date: 02/04/1999
Submittor: Maine Medical Examiner Cond. of Spec: S
Filter Paper: 865093 Baby's Name: BORTNER, CASSIDY Sex: F
Newborn ID: 1209017 AKA Name:
Accession No: 2000185039 Med. Rec. No: 2000-1862A
Mother's Name: Physician: GREENWALD

Autopsy Specimen Report

| <u>Screening Test</u> | <u>Outcome</u> |
|--------------------------------|----------------------|
| Acylcarnitine Profile | Within Normal Limits |
| Biotinidase Deficiency | Within Normal Limits |
| Congenital Adrenal Hyperplasia | Within Normal Limits |

Comments:





National Medical Services, Inc.

Toxicology Specialists Worldwide Since 1970

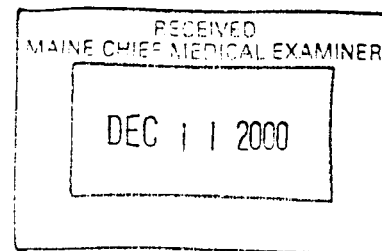
3701 Welsh Road
Willow Grove, PA 19090
Phone: (215) 657-4900
1-800-522-6671
Fax: (215) 657-2972

1137

CONFIDENTIAL

December 6, 2000

TO: Office of the Chief Medical Examiner
State House Station #37
Augusta, ME 04333



TOXICOLOGY REPORT OF:
NMS Control No.: .

BORTNER, Cassidy
621526

(2000-1862A)

21mos/F

SPECIMENS: Two grey top tubes (one containing ~ 4.5 mL blood and one containing ~ 6.5 mL blood) were received on 11/17/00.

EXAMINATION: Analysis Requested - Test Panel 8109 - Therapeutic Drug Monitoring, Abused Drugs, Carbon Monoxide and Cyanide Screen.

FINDINGS:

Blood

CARBOXYHEMOGLOBIN
(by Spectrophotometry)

Less than 2 % Saturation

Other than the above findings, examination of the specimens submitted did not reveal any positive findings of toxicological significance by procedures outlined in the accompanying "Analysis Summary."

COMMENTS:

Hemoglobin is a protein found in red blood cells that is responsible for the oxygen carrying capacity of blood. In normal conditions, hemoglobin receives oxygen via blood circulation through the lungs and delivers the oxygen to tissues and organs throughout the body. In situations where the inspired air is high in carbon monoxide concentration, the hemoglobin then binds the carbon monoxide in place of oxygen. This leads to a functional deficiency in oxygen delivery to the organs and tissues of the body. Measurement of carbon monoxide hemoglobin saturation gives an indication of the carbon monoxide concentration in the inspired air and its possible sequelae. Normal endogenous carboxyhemoglobin levels are generally up to 4% in non-smokers and up to 8% in smokers; toxic symptoms may be noted at levels >10%. Concentrations over 10% saturation have been reported to produce adverse effects, e.g., headache and nausea. Deaths from carbon monoxide, in the absence of resuscitative measures, generally have associated carboxyhemoglobin levels >40%. However, individuals with a compromised cardiovascular system are at a potentially greater risk of toxic effects at much lower carbon monoxide hemoglobin saturation values.

Respectfully

Lee M. Blum, Ph.D., DABFT
Forensic Toxicologist

LMB/sdw

CONFIDENTIAL

NMS Control No.: 621526

Page 2

1138

This analysis was performed under chain of custody. The chain of custody documentation is on file at National Medical Services, Inc.

The data generated in the determination of the results contained in this report are scheduled to be discarded eighteen (18) months from the date of the original report, unless alternate arrangements are made by you prior thereto.

The remainder of the submitted specimens are scheduled to be discarded six (6) weeks from the date of this report unless alternate arrangements are made by you prior thereto.

***** ANALYSIS SUMMARY *****

8109 - Therapeutic and Abused Drugs, Carbon Monoxide and Cyanide Screen Panel

Test No. 8109 - Drug Screen by Enzyme Immunoassay on Blood for: Amphetamines, Barbiturates, Benzodiazepines, Benzoyllecgonine (Cocaine), Cannabinoids (Marihuana), Methadone, Methaqualone, Opiates, Phencyclidine (PCP) and Propoxyphene.

Test No. 0171- Alcohol Screen - Enzymatic Assay on Blood for: Ethanol (Ethyl alcohol).

Test No. 8109 - Alcohol Panel - Headspace Gas Chromatography on Blood for: Methanol, Ethanol, Acetone, Acetaldehyde and Isopropyl Alcohol

Test No. 8109 - Drug Screen Panel II - Gas Chromatography of Extracts on Blood for: Belladonna-, Cinchona-, Ergot-, Methylxanthine- and Strychnos-Alkaloids, Amphetamine and Amphetamine-like Sympathomimetics, Antiepileptics, Antihistamines, Antipsychotics (including Phenothiazines, Tri- and Tetracyclics), Barbiturate and Non-Barbiturate Hypnotosedatives, Local Anesthetics, Non-Digitalis Cardioresgulators, Non-LSD Hallucinogens, Oral Hypoglycemics (Tolbutamide, Chlorpropamide), Synthetic Anticholinergics, and Synthetic Morphine Substitute Narcotic Analgesics.

Test No. 8109 - Carbon Monoxide - Spectrophotometry on Blood for: Carboxyhemoglobin.

Test No. 8109 - Colorimetric Analysis on Blood for: Acetaminophen, Salicylate and Ethchlorvynol.

Test No. 8109 - Cyanide - Spectrophotometry on Blood for: Cyanide.

***** END OF REPORT *****

**MAINE STATE POLICE
CRIMINAL INVESTIGATION DIVISION I
CONTINUATION REPORT**

1139

INCIDENT #: 20-4-35897

**CASE: HOMICIDE
(KASSIDY BORNTER)**

OFFICER: DETECTIVE JEFFREY SMITH

I.D. #: 4445

Approved: *MJS*

03-09-2001

1100

I received from DETECTIVE LANCE MCCLEISH via regular mail the original audio tape interview of JENNIFER CONLEY (DOB 04-17-80) conducted by DETECTIVE MCCLEISH and me dated 11-10-00. I turned the original audio tape over to DETECTIVE BLODGETT after making copies.
See Transcript.

RECOMMENDATION:

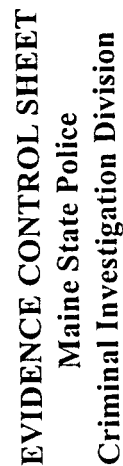
A copy of this report to be incorporated in the case file.

ENCLOSURES:

Tape Transcripts of: JENNIFER CONLEY (DOB 04-17-80)
Evidence Control Sheet

DISTRIBUTION:

DETECTIVE JEFFREY LINSOTT
DETECTIVE JEFFREY SMITH
CID I
HQ
SERGEANT DETECTIVE JAMES WHITE NH STATE POLICE
NH AG



Officer: Det. J. Smith
Case No.: 20-4-35897
Lab No.:

[illegible]