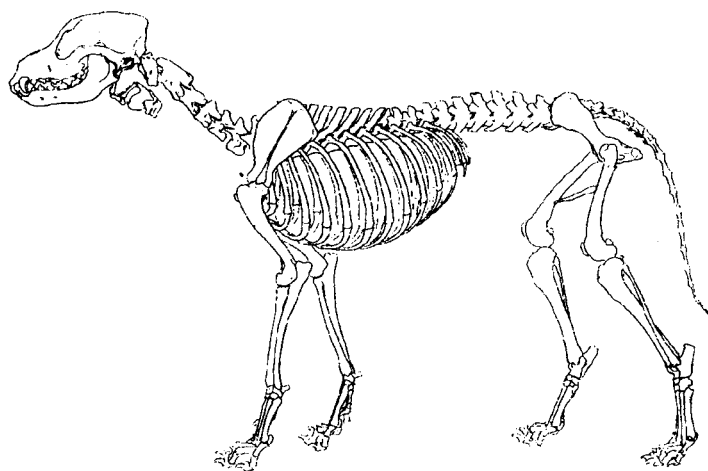
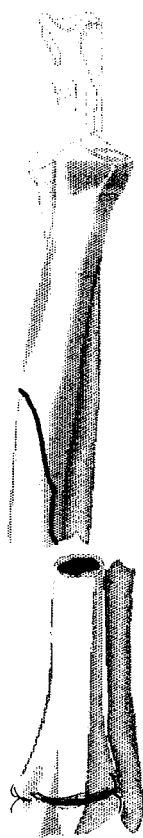


**DOVER
VETERINARY
HOSPITAL**
REFERRAL LETTER

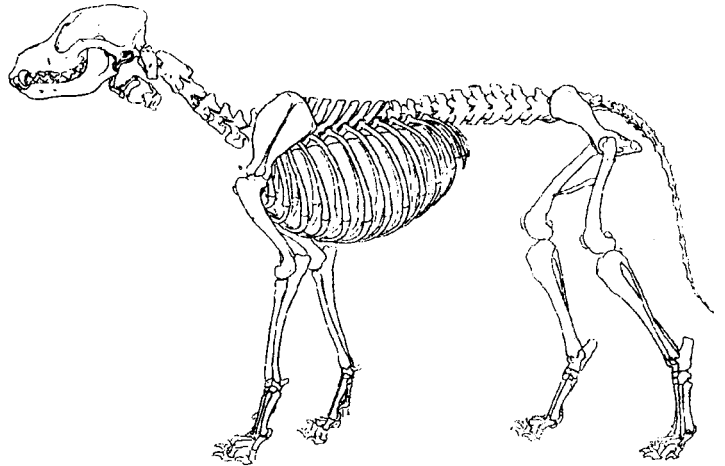


To: **Dr. Bill Lowe**
From: **Dr. Peter L. Wadsworth**
Date: **January 8, 1995**
Owner: **Chad Evans**
Animal's Name: **Kato**
Reason for Referral: **Fractured left Radius & Ulna**



The figure above represents the findings on the radiographs you sent with Kato. I agreed with your diagnosis and recommended internal fixation. The owner agreed and the surgery was done on November 15, 1994.

**DOVER
VETERINARY
HOSPITAL**
REFERRAL LETTER



To: **Dr. Bill Lowe**
From: **Dr. Peter L. Wadsworth**
Date: **April 20, 1995**
Owner: **Chad Evans**
Animal Name: **Kato**
Reason for Referral: **Plate removal from left Radius**

Update: Nov. 14, 1994 referred for fractured left radius and ulna. Repaired with plate and screws (see letter of Jan. 8, 1995). March 2, 1995 Kato was seen for fistula distal to radial plate on the left fore leg. I recommended removal of the plate and screws and the owner agreed. The surgery was done on March 24, 1995 and Kato made an uneventful recovery from the anesthesia and surgery. He was seen again on April 13, 1995 and doing very well. There was no more drainage from the leg.

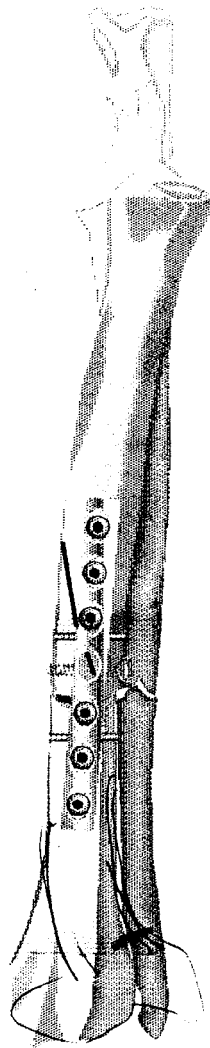
Kato has developed a mild to moderate valgus deformity due to a premature closure of the left distal ulna physis. I recommended correction of the deformity but the owner is unable to afford the surgery at this time. I told the owner it might be possible to get away without it and time would tell.

If there is any other information you would like, please let me know.

Sincerely,

Peter L. Wadsworth, VMD

Burby / Burby



The figure above represents the surgery done on Kato.. The surgery went well and he made an uneventful recovery from anesthesia and surgery. Kato was discharged on November 18, 1994 with instructions to leash walk only long enough to take care of body functions. You saw him to repair the bandage sometime around the 21st. We saw him on December 6, 1994 and he was doing well except that he had already removed his bandage which we left off. Kato was seen three days later for severe licking of the surgical site and was put on antibiotics. He was rechecked on December 12, 1994 with some swelling of the caudo-distal aspect of the surgical area. On January 4, 1995 he was doing better but there was still a little swelling and pain in the area. We left him on antibiotics for another week.

Thank you for the referral. If there is any other information you would like, please let me know.

Sincerely,


Peter L. Wadsworth, VMD

Tufts Veterinary Diagnostic Laboratory
200 Westboro Road
Grafton, MA 01536
(508) 839-7900

Accession No.: 96.142055
Date Received: 10/10/96

Trypsin-like Immunoreactivity Report

Mail To:

BROADVIEW ANIMAL HOSPITAL
DR. WILLIAM LOWE
134 TEN ROD ROAD
ROCHESTER, NH 03867

Phone: 603/335-2120
FAX: 1-603-335-0331

Route: MI
Type: AUTO FAX

Customer No.: BROADVIE

Doctor:	CAMPBELL	Species:	CANINE
Owner:	EVANS	Breed:	SHEPX
Patient:	KATO	Sex:	M
Patient I.D.:	N/A	Age:	2 yrs. / 4 mos.

Result: 9.3 ng/ml

Comment: Normal values for TLI: 5 - 35 ng/ml

Date Read 10/15/96

Name (last, first): Harvey, Brandon & Nicole - 19129-1 caution
 Street: 43 Milk Hill Rd. MI 4105
 PO Box/Apt.: _____ AME Kato
 City/Town: Belmont State: NH ZIP: 03220 ~~Chester, NH~~ ZIP _____
 Home Phone: 524-0430 Work Phone: _____ T TIME TO CALL _____

SPECIES Canine COLOR white SEX MN BIRTH DATE 6/16/94
 BREED Shep x golden IMMUNIZATION RECORD DHL _____ DHLP _____ MEASLES _____
 WEIGHT _____ HEARTWORM _____ F.D. _____ FVR-CV _____ RABIES _____

PREVIOUS PROBLEMS _____ HISTORY _____
 CURRENT PROBLEMS _____

SPECIAL PROBLEMS

DATE			PROBLEM NUMBER	SOAP FORMAT	PROGRESS NOTES	FEE	PAID	BALANCE
MO	DAY	YR						
8	11	94			DHPP/CV I wt. 12.6 Int. Sm #1 * R/P 1/2 cu - repeat s/p next visit 4 wks	24 23		
9	3	94			DHPP/CV II wt. 22 eating well, housetraining well. vac FE - normal healthy puppy Pet Tabs 60 Pearlescent Shampoo re ✓ 5 wks last DHPPCV + RV	29.25 24		
10	8	94			DHPP/CV III wt. 32# RV 20563 rx. int M#2	36 36		
					remove hind dewclaw at D/N jumpy - PE(N)			
11	14	94			Fractured radius - ulna (left) ABC will need pin or plate emergency clinic - Sunday noon Xray shows fractured Radius + ulna (left) (midshaft radius, distal ulna) discuss options of repair			

DATE			PROBLEM NUMBER	SOAP FORMAT	PROGRESS NOTES	FEE	PAID	BALANCE
MO	DAY	YR						
11	14	94			most desirable - plate least desirable - casting + splinting transferred to Wadsworth			
11	21	94			Bandage change Robert Jones Bandage reappplied (lg) E-collar dispensed to use for chewing			
2	25	95			vomiting on and off wed. + sat even wt 5lb. mostly bile + foam same food and treats rotin garbage at all. No diarrhea PE - HR RR normal, abd- palp. normal unable to temp. Left leg deviated laterally and has a draining tract as well. Rx - Canine I/D 7 cans 1 can BID 3 days 4th day 1/2 can w/ reg food - 400mg Amoxi BID 7 days highly recommend rer with Dr. Wadsworth. Owners let dog out of cage early	20 ⁰⁰		
11	20	95			Back left paw (laceration) wt. 57 quote \$100 laceration exam between web of toes also some of pad missing 2cc Amoxi in clipped + cleaned placed 4 sutures in sk skin fold bandaged 20cc Pentathal IV anasth Rx: Amoxicillin 400mg BID 7 days had surgery at Dr. Wadsworth's removed sequestrum. - doing great			

PROGRESS NOTES

Harvey
Hans, Chad

Kato

shep X

Wht

MN 6-94

OWNER'S NAME

PATIENT'S NAME

BREED

COLOR

SEX

BIRTH DATE

DATE			PROBLEM NUMBER	SOAP FORMAT	PROGRESS NOTES	FEE	PAID	BALANCE
MO.	DAY	YR.						
4	21	95			B.A.R. bandage o.k. Rx - Amox; 400 BID 7 days DSO Ritchie rev 5 days to A bandage.	10.70		
4	26	95			A bandage healing well. reapplied bandage rev 5 days bandage and SIR will pay at next visit			
5	1	95			Re ✓ SIR ⊙ healed well			
6	14	95			HWD Rx - INL #3 Preventic Lab Rx			
					→ Back leg better for HW			
10	24	95			DHLPP/CV ⊙ wt. 59 lbs RV ⊙ tag # ⊙ 23191 few flus seen Rec - abuse Tr Rec Program - 1 dog 2 cats suggested flea program - for everyone Int. Care # 12 Program # 12 1 cat over 14 lbs 1 kitten (6 mos.)			

DATE			PROBLEM NUMBER	SOAP FORMAT	PROGRESS NOTES	FEE	PAID	BALANCE	
MO	DAY	YR							
12	20	95			<p>✓ leg (circled) front wt. 60 lb</p> <p>piece of suture material hanging out. pulled & clipped (circled)</p> <p>Intra-rac II vac (circled)</p>				
8	13	96			<p>Muzzle</p> <p>HWA (circled) wt. 59.8 lbs</p> <p>Nail trim (circled)</p> <p>↳ front! careful</p> <p>Ins ← →</p>			23	
10	4	96			<p>Vomiting + diarrhea wt. 50.</p> <p>to one day</p> <p>losing wt.</p> <p>(circled) will muzzle</p> <p>vomited bile many times yesterday - soft stool/diarrhea since yesterday</p> <p>excellent appetite</p> <p>PE: very aggressive</p> <p>P 104 mm pink thin non-painful</p> <p>R/O bacterial enteritis/gastritis</p> <p>EPI</p> <p>parasites (circled)</p> <p>tried to draw CBC + TLI TLI -</p> <p>could not due to dog's attitude</p> <p>Rx: Amoxi 400mg BID x 10 # (circled)</p> <p>Amforal 2 tabs BID x 3 # (circled)</p> <p>NPO til tonight then small, bland meals</p> <p>will need to sedate for bloodwork</p>			53	
					<p>called lab: wants to do TLI</p> <p>Rx Ace 25mg 7 Give 1-2 hours before visit # (circled)</p> <p>10mg #1 each</p> <p>Set up for 1-2 hrs, when over current hour</p>			3.35 # (circled)	

Harvey
Erans
 OWNER'S NAME

Kato
 PATIENT'S NAME

Shurx
 BREED

White
 COLOR

MM 6/16/94
 SEX BIRTH DATE

DATE			PROBLEM NUMBER	SOAP FORMAT	PROGRESS NOTES	FEE	PAID	BALANCE
MO.	DAY	YR.						
10	7	96			TLI Pull Blood for $\text{\textcircled{D}}$	$\text{\textcircled{0}}$		
10	10	96			✓ Newerx incision, open remove dewclaw bandage wrong record			
10	16	96			lab results tu 9.3 (N5-35) ↓ normal - equivocal also rec prophylactic rital x 3 days → maybe start low levels of vidase called to ST roommat. will call back ical neg			
10	21	96			Rx Rital 56# sig x 3 days	$\text{\textcircled{9.30}}$	$\text{\textcircled{18.30}}$	9
6	25	97			wt. 59.8 DHPP/EC ✓ H/W/Sg ⊖ INL #120 Aggression problems Alln + gfa o/a absorbable sabs & sutures ⊖ DIN ⊖ + 1/2 dewclaw removal ⊖ ⊖ 25 more 20cc pent $\text{\textcircled{NIC}}$ LN $\text{\textcircled{45}}$ anal $\text{\textcircled{40}}$ 221.50 $\text{\textcircled{H 813}}$			
					All incisions closed with absorbable suture no S/R needed Have to remove dewclaw bandages at home 3 days.			
5	14	98			✓ over, was in a fight box Ate squirrel this morning wt. & was bitten on the nose by it No visible wound - Dog fire RV			38

DATE			PROBLEM NUMBER	SOAP FORMAT	PROGRESS NOTES	FEE	PAID	BALANCE
6	26	98			<p>wt. 66</p> <p>✓ left eye - small lesion on cor. Rb eye brown</p> <p>✓ front paw</p> <p>ALSO has been vomiting x 2 weeks</p> <p>DHURP/CVO } wait</p> <p>HW } wait</p> <p>Doesn't need HW pills</p> <p>- difficult to exam - biting + wait allow muzzle to be put on to strip grass brown</p> <p>R/O basket</p> <p>R/ Anaxi 400g 1 bid x 2d</p> <p>R/ Metronidazole 10mg 1 bid x 7d</p> <p>R/ Fagant 300g 1 bid x 2d</p> <p>R/ EW dry 10#</p> <p>dog well rec. w/er</p> <p>HW in 2 wks - take dog from owner before putting in the exam room</p>			
7	29	99			<p>o believes that may have intestinal parasites, as is eating more & somewhat listless</p> <p>fecal @ neg</p> <p>gross sample i neg</p> <p>o to call later for results; need complete history & rec. apt if still lethargic</p> <p>(wt 60)</p>			
7	17	00			<p>✓ limping on (L) front leg</p> <p>(overdue for DP+HW)</p> <p>H/O Radius/Ulna fx repaired 11/94 - with removal of plate 3/95 at fistula formation. Pre Mature growth plate closure found 4/20/98 - Dr Wads worth rec. correction o declined</p> <p>2 wks duration of lameness - was very active prior to onset</p> <p>unable to examine - biting</p>			

Harvey

19129-1 TO 1507

PROGRESS NOTES

Caution

OWNER'S NAME Evans	PATIENT'S NAME Kato	BREED Shep	COLOR white	SEX M/N	BIRTH DATE 6/94
-----------------------	------------------------	---------------	----------------	------------	--------------------

DATE			PROBLEM NUMBER	SOAP FORMAT	PROGRESS NOTES	FEE	PAID	BALANCE
MO	DAY	YR						
7	17	00	Cont.		Rec. Rimadyl 100 mg 1/2 BID x 14 days rel and drop off for sedation & rad's	45.00		#1387
2	21	02			<p>✓ lump on stomach (70 #)</p> <p>DHPP/CR ✓ VAX</p> <p>3DX 0 Lyme 0 Ehr 0 HW</p> <p>anyone within the past 10 days.</p> <p>anyone within the past 10 days.</p> <p>RV 3 yr. ✓ #</p> <p>3B</p> <p>swear that to my knowledge the following animal has not bitten anyone within the past 10 days.</p> <p>(n) 0, Transferred from Chad Evans to Harvey EB</p> <p><u>aggressive</u></p> <p>Rx - Acpromazine - 25mg 2 pills or even 3 pills 1 hour prior to visit #8</p>	57.00	paid VISA	
9	15	03	(cont)		<p>(wt. 65 #)</p> <p>DHPP/CR ✓</p> <p>3DX 0 Lyme 0 Ehr 0 HW ✓</p> <p>Dr. to discuss HW & flea & tick prevention</p> <p>PE: Fleas - all else wnl</p> <p>A: Fleas</p> <p>Frontline ✓</p> <p>HTGD</p>	187.00	paid VISA	

